

Curriculum 1

Lecture 1

Thoracic Paravertebral Block (TPVB):

Introduction, anatomy, basics of ultrasound and sonoanatomy for TPVB

Why do you need to learn all that?

- TPVB is a very useful block (see table for common indications)
- Ultrasound is a great tool in modern medicine and the basic principles are the same and transferable

Postoperative analgesia

Thoracic surgery

Breast surgery

Cholecystectomy

Renal and ureteric surgery

Herniorrhaphy

Appendicectomy

Video-assisted thoracoscopic surgery

Minimally invasive cardiac surgery

Surgical anesthesia

Breast surgery

Herniorrhaphy

Chest wound exploration in a single lung transplant recipient

Acute postherpetic neuralgia

Chronic pain management: benign and malignant neuralgia

Miscellaneous

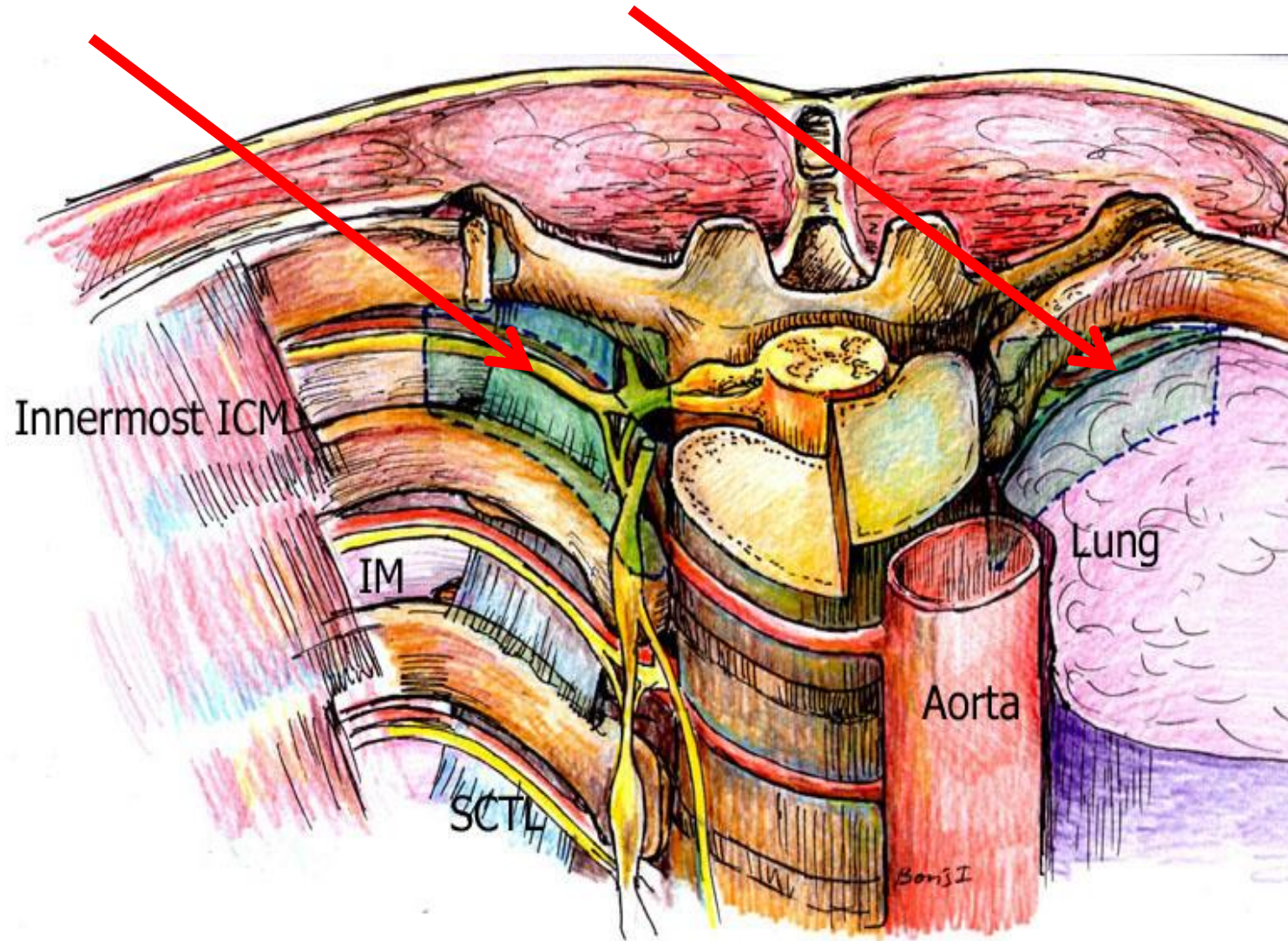
Fractured ribs

Therapeutic control of hyperhidrosis

Liver capsule pain after blunt abdominal trauma

TPVB is the injection of local anesthetic (LA) into the Thoracic paravertebral space (TPVS) in order to **produce an ipsilateral segmental somatic and sympathetic block**.

TPVS is a wedge-shaped space that lies on either side of the vertebral column, in between the heads and necks of the ribs



Anatomic Boundaries of TPVS and its content and communications

Boundaries:

Superior/Inferior- head and neck of the ribs

Anterior -parietal pleura

Posterior –medially: lower part of TP, superior costotransverse ligament (**SCTL**); laterally: internal intercostal membrane (**IIM**) - a fibrous continuation of internal intercostal muscle. External intercostal muscles and levators costarum are dorsal to IIM

Medial - postero-lateral aspect of the vertebra, the intervertebral disc and the intervertebral foramen

Lateral- Imaginary plane through lateral edge of neck of the rib (technically it extends few cm past costo-transverse junction)

Contents of interest: spinal nerves, sympathetic chain

Communications:

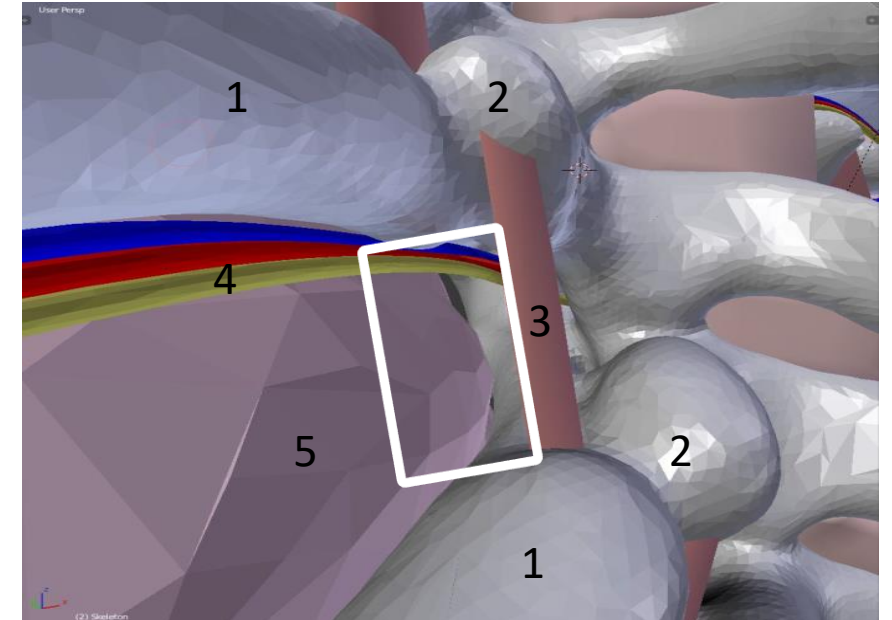
above and below: adjacent TPVSs

medially and anterior epidural space, mediastinum

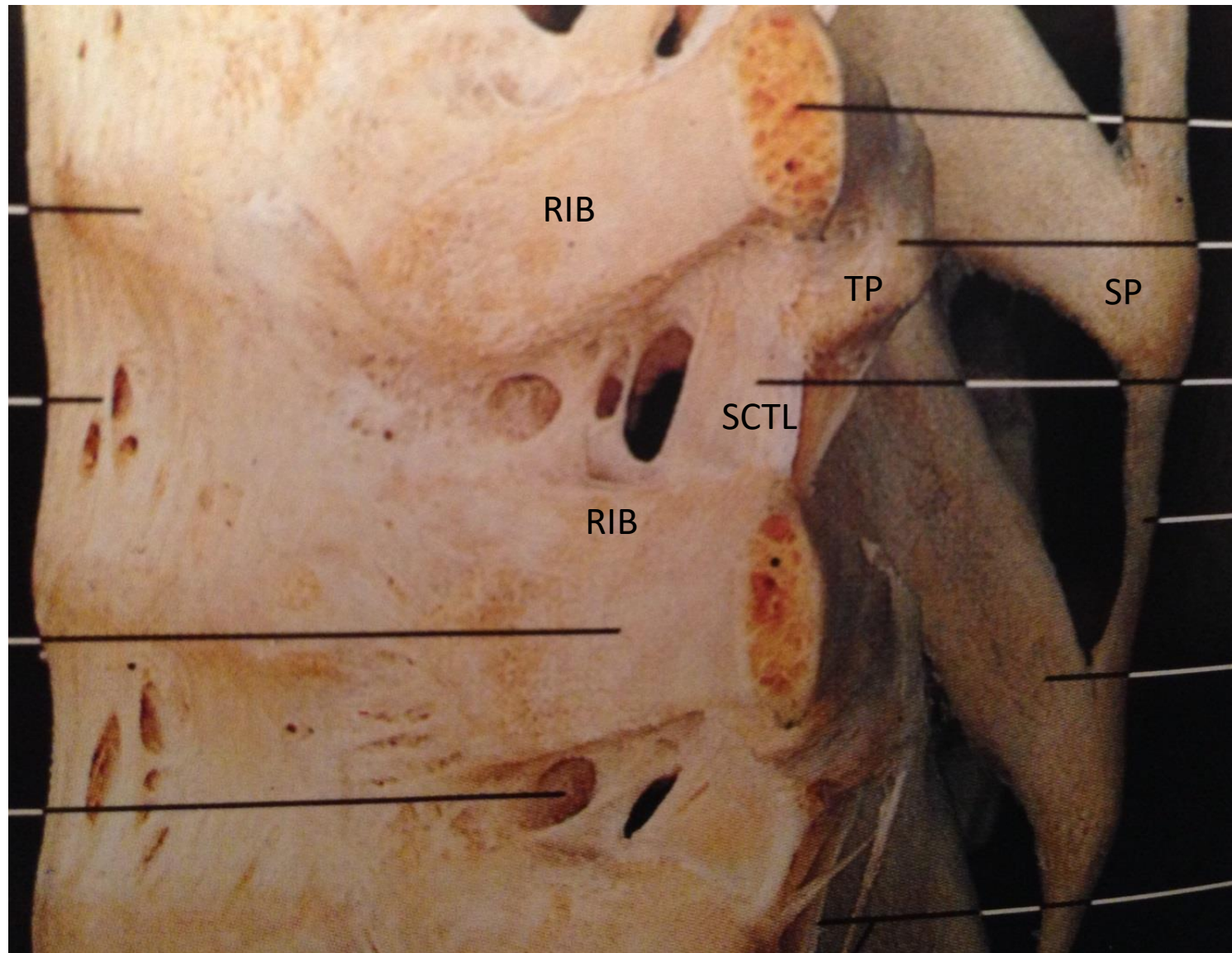
laterally: intercostal space

Cranially the large bolus may occasionally extend to the brachial plexus but it stops at L1 (psoas muscle attachment) for a maximal caudad spread

Left TPVS. Paramedian sagittal view



- 1) Rib
- 2) Transverse process
- 3) Superior costotransverse ligament (**SCTL**)
- 4) Neurovascular bundle
- 5) parietal pleura
- 6) TPVS

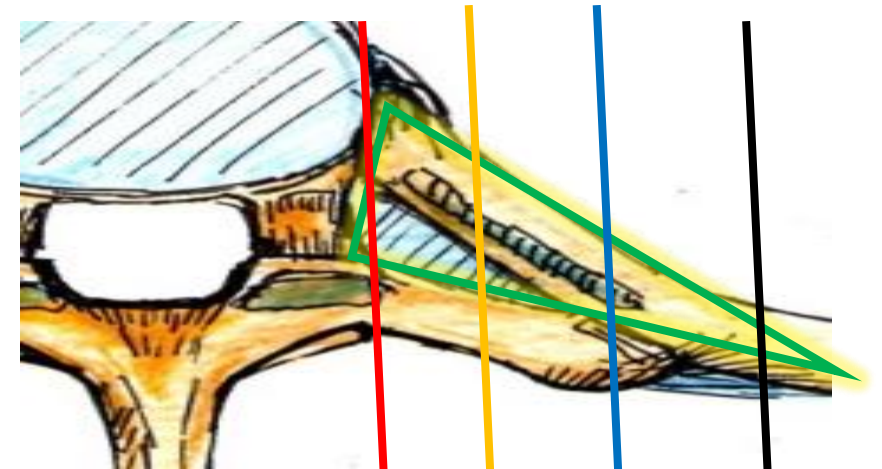
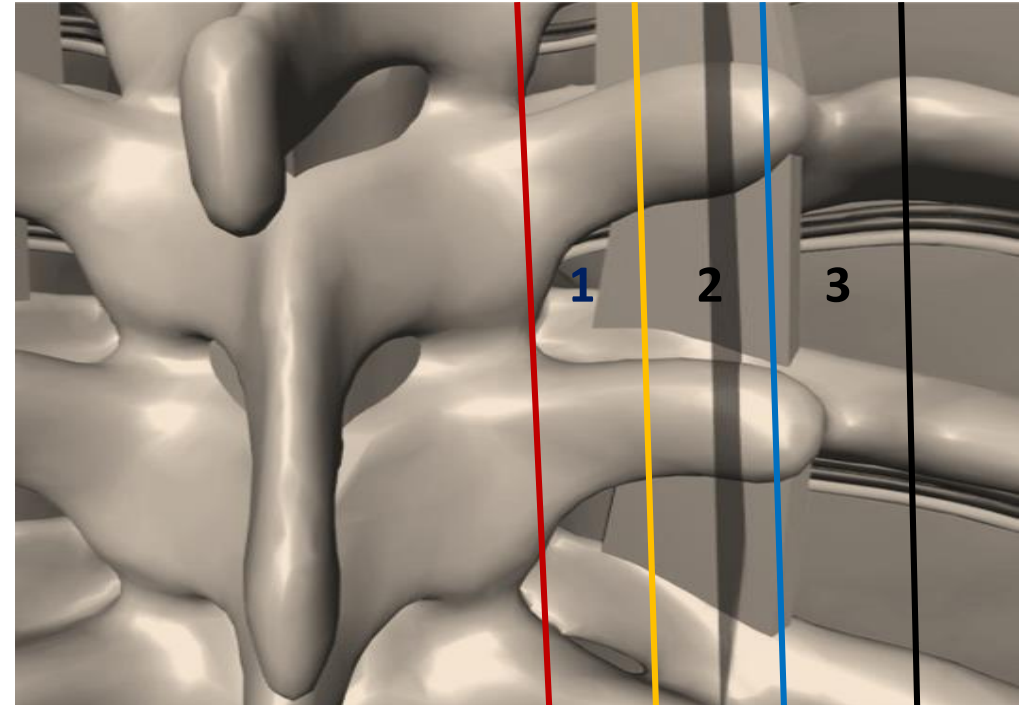


View from the left side (ribs cut close to TPs)

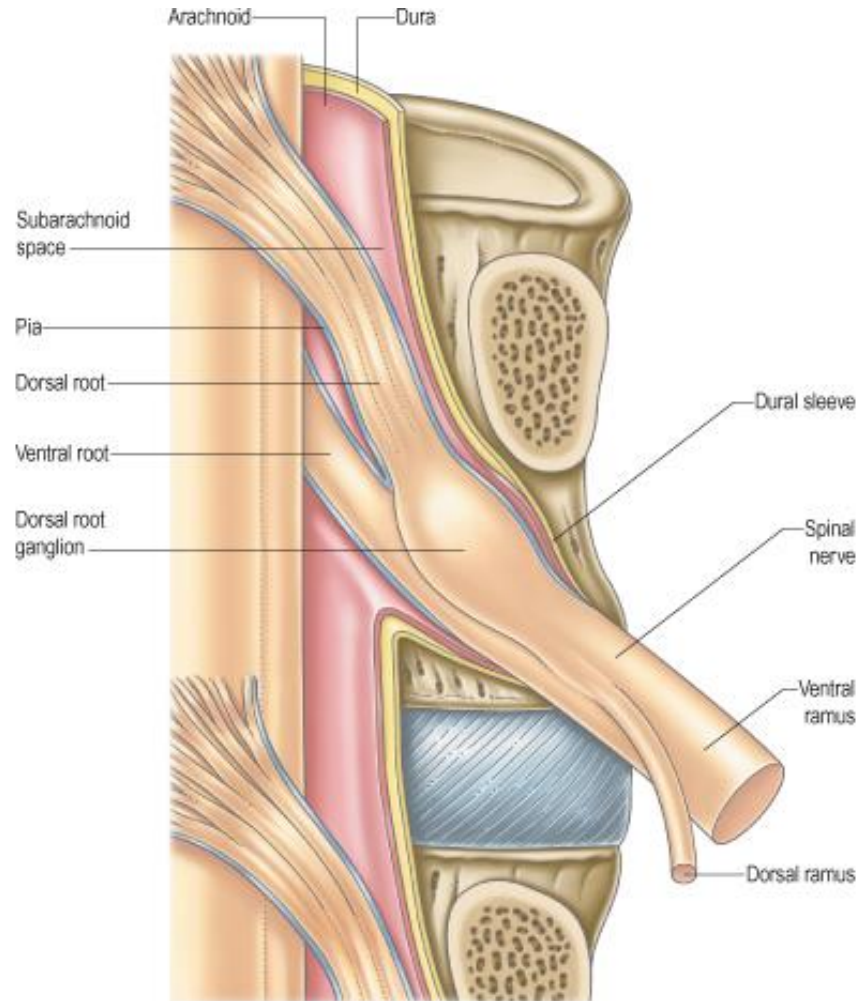
Note that SCTL has slight oblique direction from cranial to caudal and from lateral to medial

TPVS could be divided into 3 zones medial to lateral

- **Medial (Zone 1):** largest AP dimension (safer for lungs), more “crowded” with bones in cranio-caudad dimension, no SCTL, risky for extensive epidural spread, risky for accidental puncture of the extended dural sleeve or vessel that feeds spinal cord. One can land on IAP and then slide into TPVS laterally or use US to get there. No man’s land in our opinion for single shots
- **Middle (Zone 2):** consistent thick SCTL (produces decent LOR), more spacious compared to lateral zone in AP-dimension (if SCTL is penetrated directly inferior to TP) but does not give the best US picture of the parietal pleura (blind/semi-blind spot). **This is where we do our US assisted and landmark based TPVB** (one can land the needle on the tip of TP and slide caudad into TPVS)
- **Lateral (Zone 3):** less distance to the parietal pleura from the posterior boundary of TPVS (only IIM, no SCTL)-still may feel LOR when needle goes from taut muscle overlying IIM to TPVS), minimal potential for epidural spread, best zone to be visualized with US

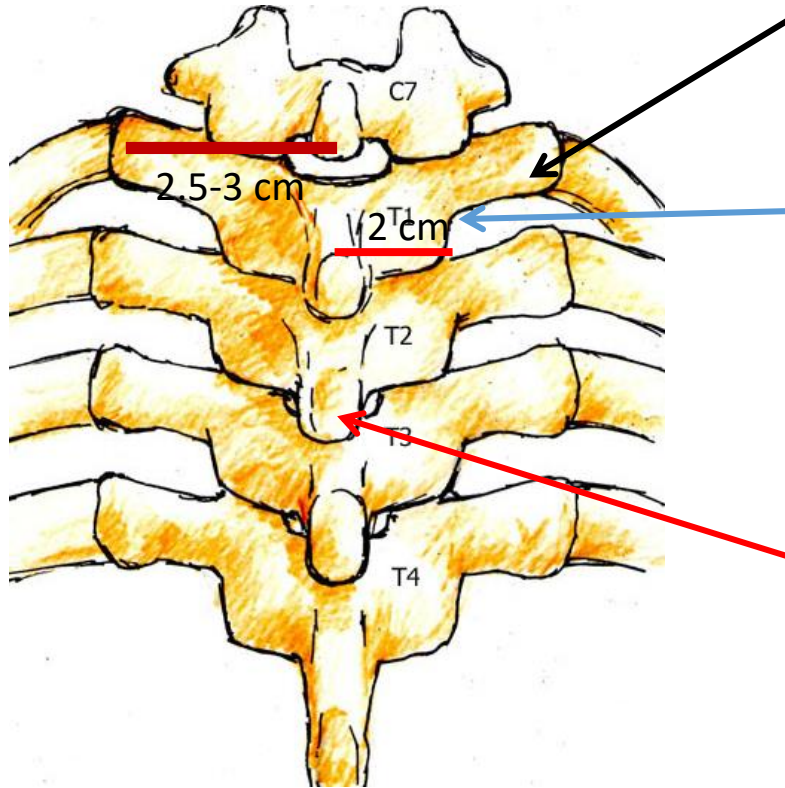


By avoiding the medial zone of the TPVS, we decrease the risk of potentially accessing the intrathecal space through an **extended dural sleeve**



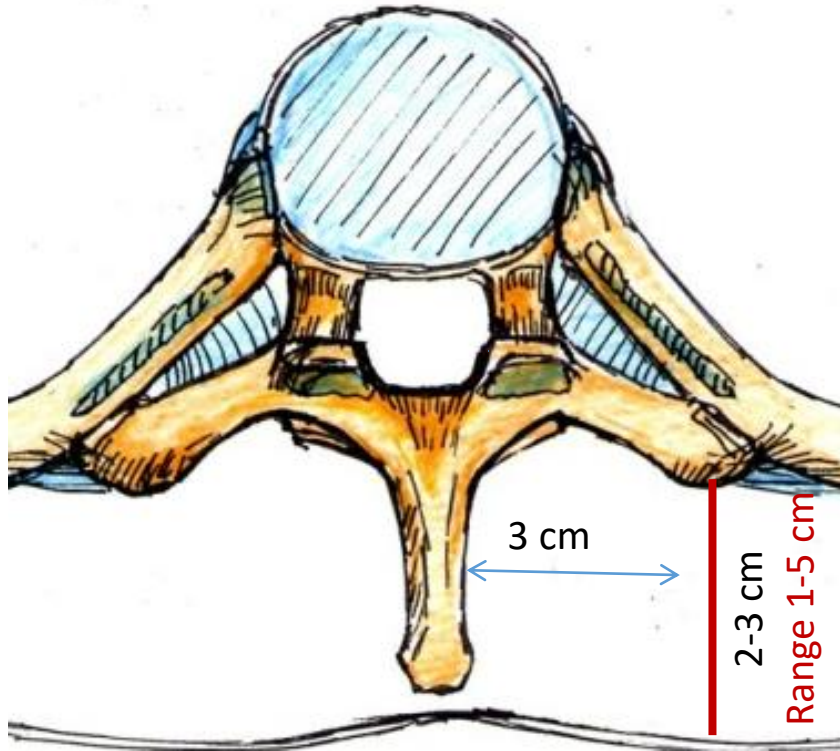
- Normally, the dural sleeve ends before the spinal nerve emerges from the neuroforamina. Occasionally, it extends into the paravertebral space.
- The chance of encountering the **dural sleeve that may extend past the neuroforamina** decreases exponentially as the lateral distance from the neuroforamina increases.
- Unrecognized large volume injection of LA into the dural sleeve will produce a **high or total spinal**.
- In addition to avoiding the medial zone of TPVS, the use of large a bore Tuohy needle is recommended in order to more easily identify dural puncture through CSF leakage

Important numbers to remember on anatomy of thoracic skeleton



- Tip of TP is on average 2.5-3 cm from midline (greater in upper thoracic levels ~ 3cm, less in lower thoracic levels and/or in smaller patients ~2.5cm)
- Lateral edge of the lamina and inferior articular Process (IAP) is about ~2 cm
- Typically, but not always, the spinous process (SP) is palpable and situated at the level of the TP of the vertebrae below: for example SP of T2 at the same level as the TP of T3
- Adjacent TPs are spaced about 1-2 cm apart (closer together in upper thorax and farther apart in lower thorax)
- TP tip is about 1 cm wide in its cranio-caudal dimension, wider in the upper thorax (1.5cm) and narrower in the lower thorax)
- TP tip AP dimension is also about 1 cm

More depths and distances of the thoracic skeletal anatomy you MUST know in order to help guide safe landing of the needle on TP



- At a paramedian sagittal plane 3 cm from midline, the depth from skin to TP tip is about 2-3 cm (but ranges from 1-5 cm)
 - depends on body habitus
 - thoracic level
 - needle trajectory
- TP is closer to skin in the mid thorax (T4-5), deeper in the lower thorax (T8-10), and deepest in the upper thorax (T1-2)

Reinforcing important anatomy, ideas, and average distances for TPVB (We recommend you memorize these points)

- We do not recommend targeting the medial portion of the TPVS due to risk of neuraxial complications (total spinal and spinal infarct). We recommend you do the TPVB more lateral at the tip of TP (2.5-3 cm from midline, in the intermediate zone). We recommend using at least a 20G Tuohy or other blunt needle with cm markings.
- Remember, at the thoracic level, any given spinous process (SP) is at the same level as the TP one vertebral level below. For example, to block the T3 nerve, mark the skin at the level of the T2 SP.
- Common palpable surface landmarks on the back:
 - SP of C7 is the most prominent SP when the neck is flexed
 - SP of T3 is at the root of the scapula spine
 - SP of T7 is at the tip of the scapula
- From midline to the TP tip is 2.5-3 cm (farther in the upper thorax and in larger patients). The lateral edge of lamina/IAP is about 1.5-2 cm from midline, and is more shallow than lung, yet about 0.5-1 cm deeper than TP tip (more so in the lower spine). The TPs in the lower spine are angled more dorsally, so they are closer to midline (do not extend from midline as much as in upper spine) and are much shallower from skin compared to lamina in AP direction.

Reinforcing important anatomy, ideas, and average distances for TPVB (We recommend that you memorize these points.)

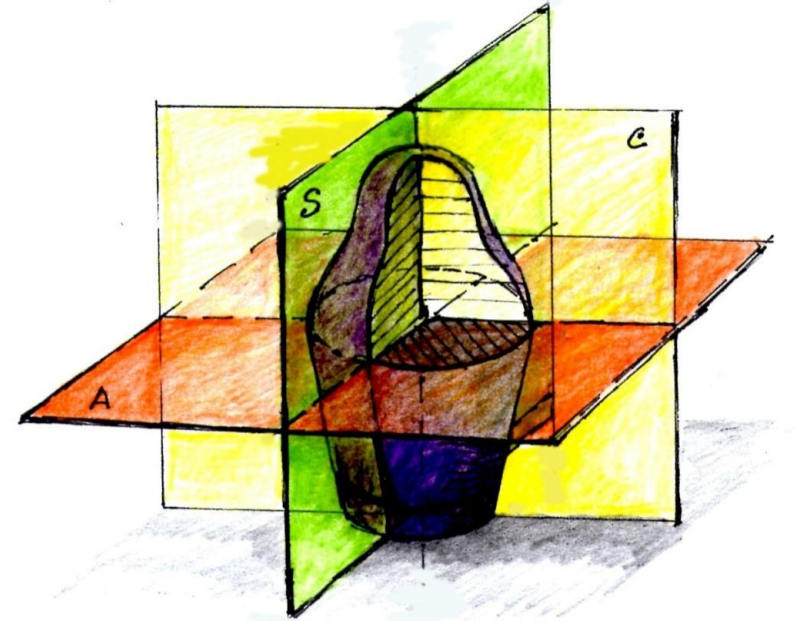
- Depth from skin to TP tip is on average is 1.5-3 cm. It is shallower in the mid thorax and deeper in the upper and lower thorax.
- From the ventral surface of SCTL or IIM to the parietal pleura is about 0.5 cm in middle zone. This distance is greater medially and less laterally (~3mm)
- At the interface of rib and TP, the rib is ventral (deeper) to the TP. The rib is also a bit cephalad to TP (upper edge of the rib is above above the upper edge of TP). However, in the upper thorax, the ribs could be completely overlapped by TP (ribs not cephalad but completely aligned with the TP). The ribs course downward from medial to lateral.

Review questions

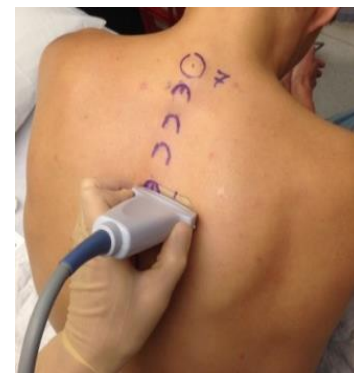- Give the definition of TPVB and TPVS
- What are the borders of TPVS
- Describe the communications of TPVS
- What SCTL stands for? What are the points of insertions of SCTL
- What is IIM? What muscles are above the IIM?
- What is special about medial zone of TPVS. Name other zones
- Name relationship of SP above and TP below? What is TP tip position (distance) from the midline and from skin? Compare different thoracic levels
- How far is lateral edge of lamina from midline, how deep is lamina compare to TP tip and lung?
- How big is TPVS in AP dimension (space between SCTL and lung) in middle zone?
- What are relationship between TP and ribs? Compare different levels
- What nerve # is below TP5? Above of TP5? What SP# do you mark to block TP5?

Planes of scanning with US

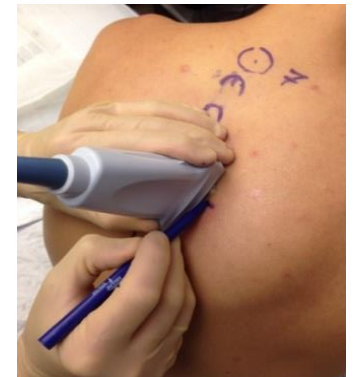
- **Scanning planes** are similar to the usual anatomical planes: **axial** (transverse), **sagittal** (longitudinal)
- When describing the **axial plane** for TPVB, we mention the level (at the cephalad edge of SP of T3 for example)
- Instead of saying parasagittal plane, it is more proper to say **paramedian sagittal** and state the distance from midline (e.g., 3 cm on the right)



A. axial(transverse) S. sagittal C. coronal



axial



sagittal

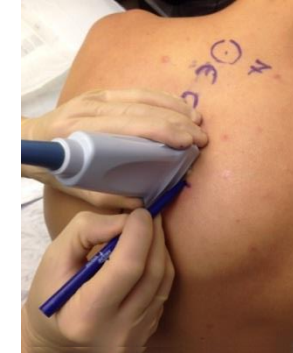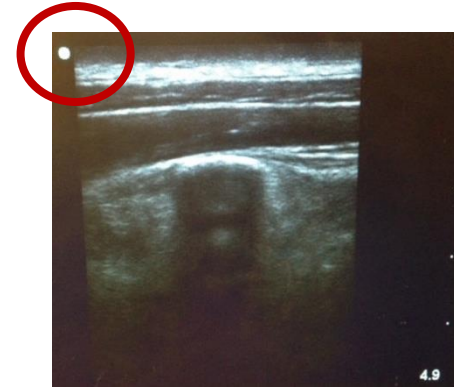
Probe and Screen orientation

In order to avoid confusion, one should always know how the probe's orientation is represented on the screen. Traditionally, the screen marker is in the upper left corner. The tactile marker on the probe corresponds to the dot marker on the US image (red circle). You should place the probe consistently in the same orientation.

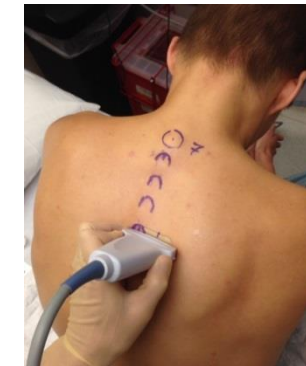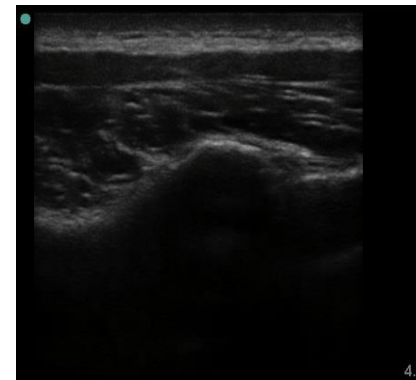
We recommend the screen marker on your US machine be set to your **upper left** when you face the screen. Most US machines allow this marker to be inverted to the other side (right hand corner, lower corner etc). As an aside, cardiac echocardiography convention is to have the marker on the upper right corner.

For thoracic RA, we recommend you always place the tactile marker pole to patient's cephalad when probe is oriented sagittally and to patient's left when probe is oriented axially. We recommend this orientation regardless of the patient's position.

For US guided TPVB with the patient prone, some may prefer to keep the probe orientation marker medially regardless of the laterality of the block



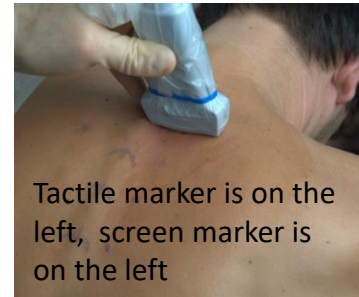We recommend that the screen orientation marker should be on your left and correspond to patient's cephalad in sagittal scan



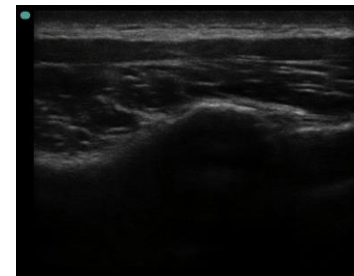
With an axial probe orientation, we recommend that the left side of the screen correlate with the patient's left.

Probe and Screen orientation (continued)

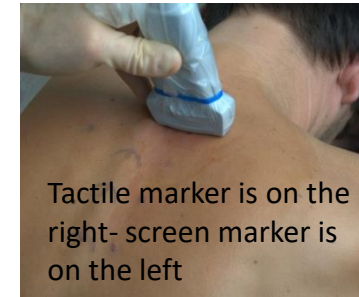- It is helpful to note in your mind both the orientation of the screen and probe: **left side of the image corresponds tomedial/lateral part of the structure** or **left side of the image corresponds to cephalad part of the structure**
- If the probe is oriented as recommended, then moving the probe in one direction will “move” the anatomical structures on the image in the opposite direction



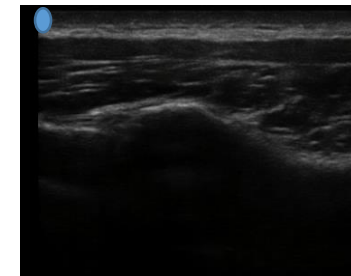
Recommended



Correct image



Not recommended

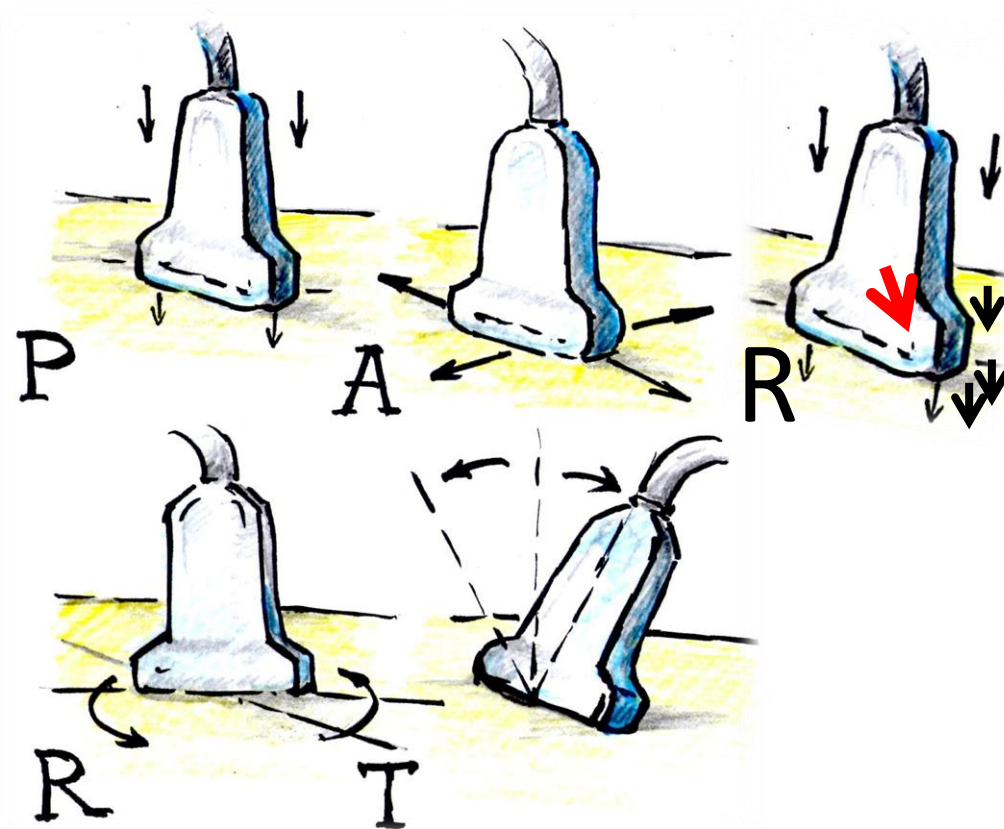


Incorrect (mirror image)

Tactile marker of the US probe should be positioned to the left.

Probe manipulation

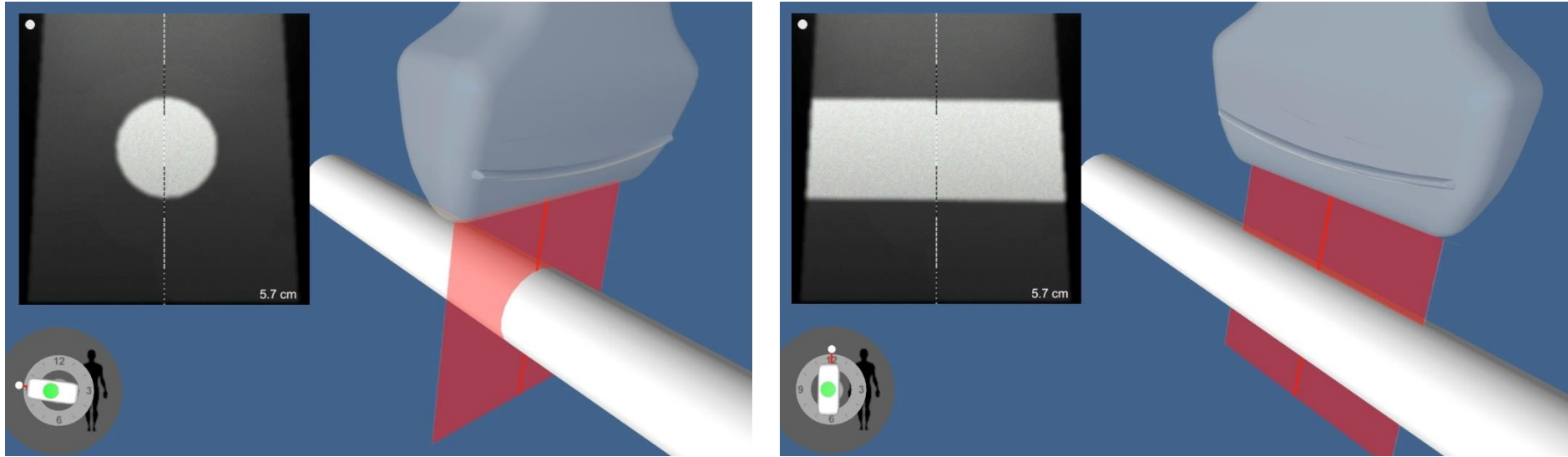
- When discussing US **probe manipulation** the “PARRT” mnemonic is useful
 - **P**ressure
 - **A**lignment (sliding)
 - **R**ocking
 - **R**otation
 - **T**ilt
-
- **Rocking** is less intuitive to understand by looking at the drawing.
 - Rocking is a case of applying more pressure on one of the poles of the probe (we often rock probe away-putting more pressure on the nose while somewhat lifting up the heel)



Terminology related to probe manipulation

- To avoid confusion we should agree on some terminology when we talk about **tilt, rotation, rocking and sliding**
- Confusion comes from the potential different reference point (patient left vs operator left) and from probe motion vs beam motion (when tail of the probe moves in one direction US beam moves in opposite direction).
- For all probe manipulation we will use a patient as a reference point and US beam movement for description of probe manipulation direction. We will try if possible to use word “US beam” instead of probe (direct beam lateral....)
- We say lateral or caudad **tilt** based on the direction on US beam: if US beam (insonating plane) moves laterally or caudad. Note again that “tail” of the probe will move in opposite direction
- When we **rock** the probe that is positioned sagittally by putting more pressure on the cranial part of the probe the beam moves in the opposite direction **caudad**. Similarly if we rock a probe that is positioned axially and put more pressure on the medial(patient wise) part of the probe beam will moves **laterally**. **This is still confusing so we may just say put more pressure on let’s say medial side of the probe.**
- When we **rotate** the probe we will **specify** if we rotate **entire probe** (both ends) relative to its axis (cord coming out of the probe can be viewed as a probe axis) or we will ask to stabilize the medial part of the probe (again patient wise) and **only rotate the lateral part of it** .
- To reflect direction of rotation we may say “clockwise” or “caudad”. To reflect the degree of rotation we may use “clock-face” terminology (from 3 to 4 o’clock) or degrees (30 degrees). Most of the time we rotate until we achieve a specific visual end point (get rid of the rib shadow on the screen, etc)
- When we talk about direction of the probe slide we again use usual terminology (cranial, medial etc) in regard of patient not operator orientation.
- Remember when we talk about probe orientation in regards of US screen we use the operator reference point. Screen mark on the left side of the screen so probe marker to the left of the operator who looks at the screen

Basic cross-sectional literacy: (cross-sections of the cylinder in short and long axis)



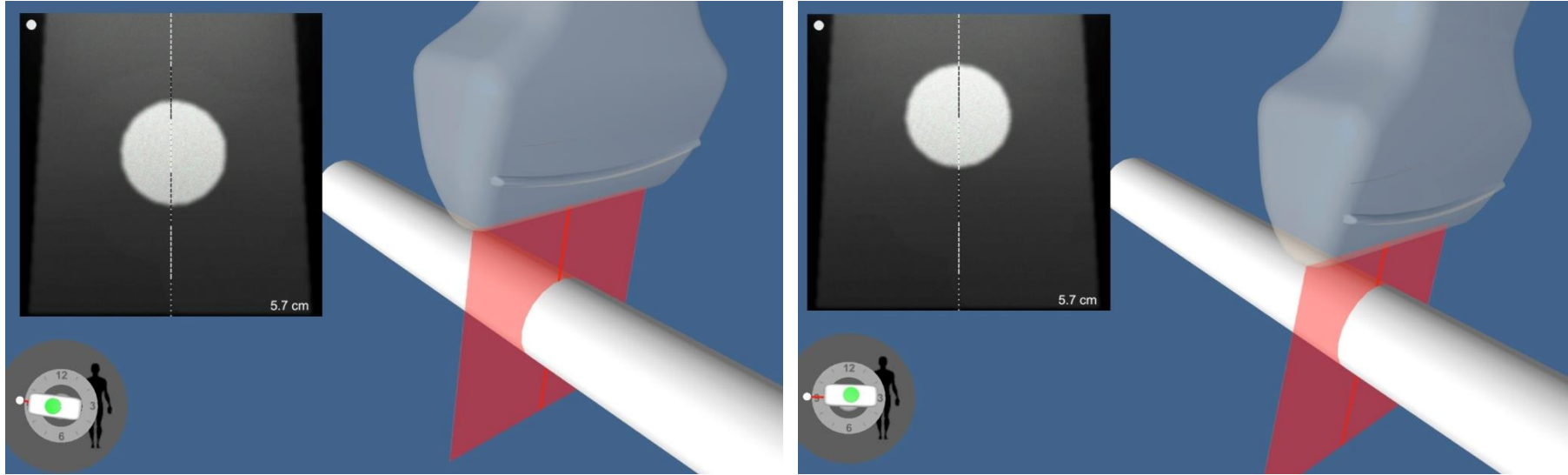
Novices will jump-start their basics of cross sectional literacy by examining the following images (pay attention to the virtual US image-black and white 2D and red virtual ultrasound plane “cutting through” the 3 dimensional object)

One of the basic shapes we with deal in medicine is the cylinder (vessel, nerve, long bone, needle, etc.)

A cylinder can be viewed in both **short axis and long axis** cross-sections. On further slides we examine how US **probe manipulation (PARRT)** will change cross-sections and cover the basics of **dynamic scanning (DS)**

DS- when based on the changes in US image during dynamic scanning over the surface of the the “black box” we can estimate the position and course of the structure provided we know its shape (here cylinder)

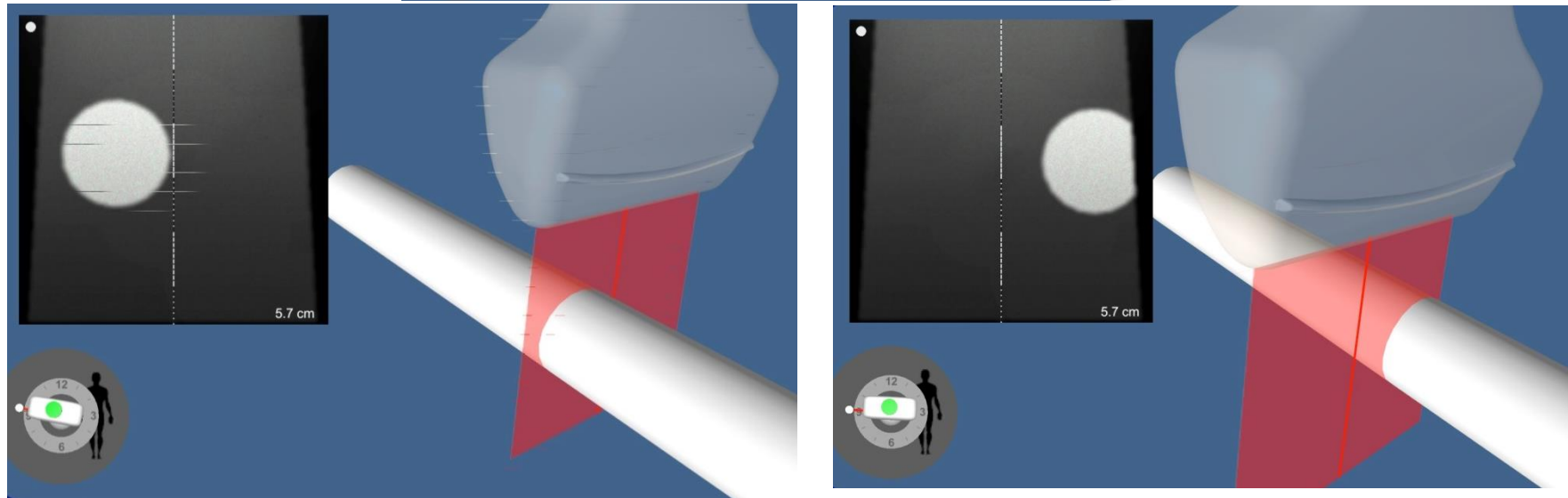
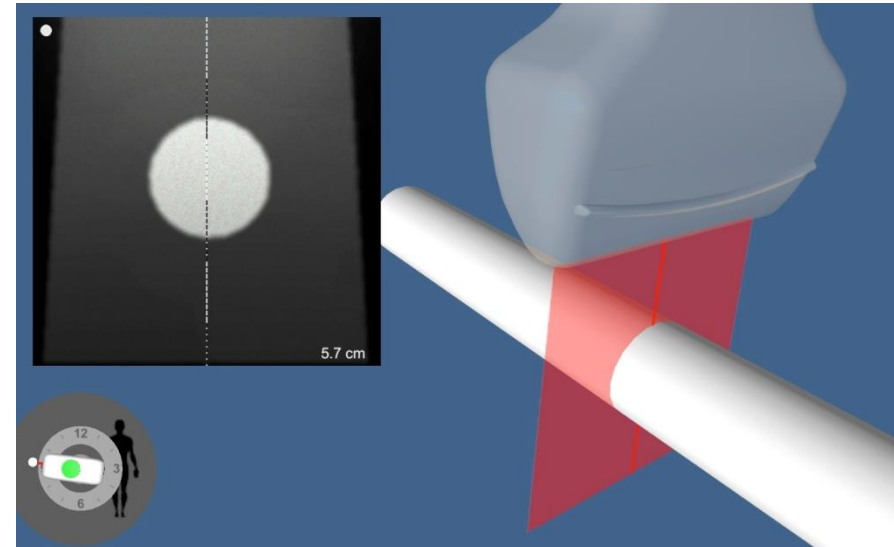
PARRT probe manipulations



Even **pressure** on the probe “brings” the image of a structure closer to the surface. This simple trick also commonly improves image quality and is frequently underutilized (be considerate to the patient though). Applying too much pressure will affect depth measurements to a target-creating an underestimation.


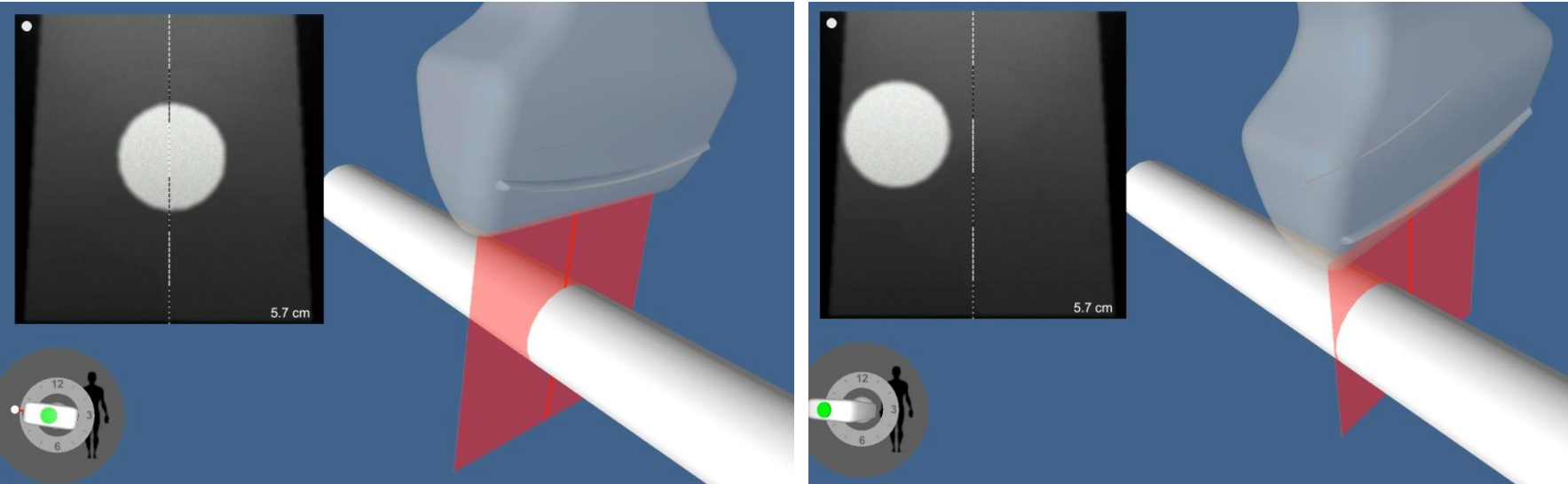
PARRT probe manipulations

Alignment or sliding the probe



Once again note that with correct orientation if probe moves left structure moves right

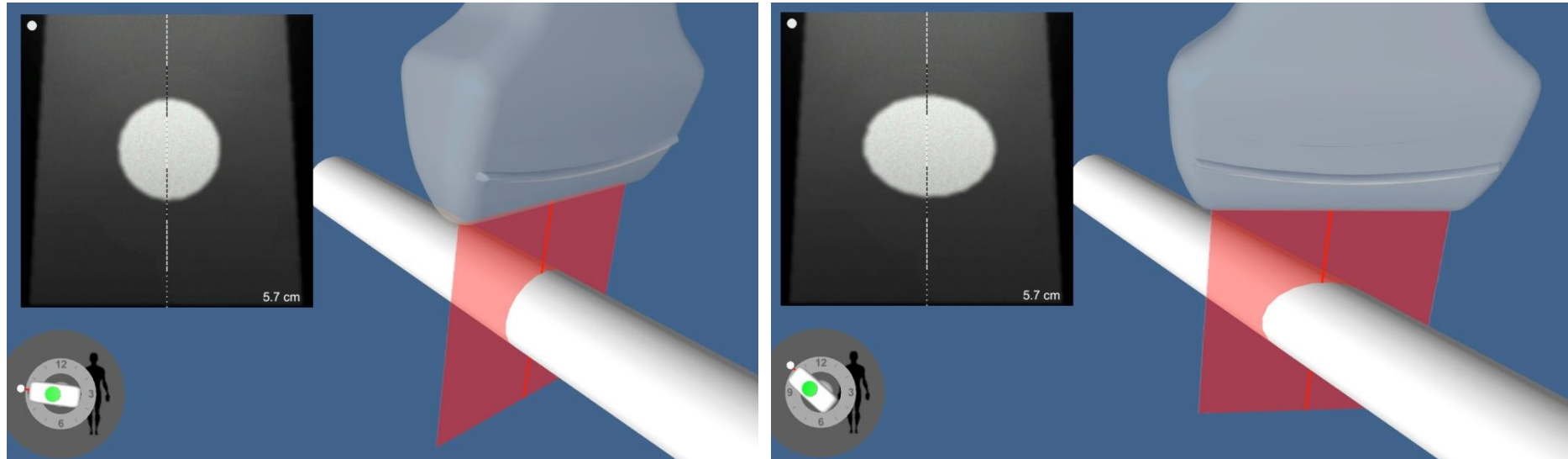
Sliding the probe so a structure is under the nose of the probe and applying uneven Pressure towards the structure (rocking the probe) is a common combo for an in-plane approach that improves the angle of incidence between US waves and the needle.



Note a more favorable angle between needle and US waves on the right. The differences get even bigger if the needle is entered a bit away from the heel of the probe (yellow line). These tricks may help to “fight” disappearing needle phenomena

PARRT probe manipulations

Rotation of the probe



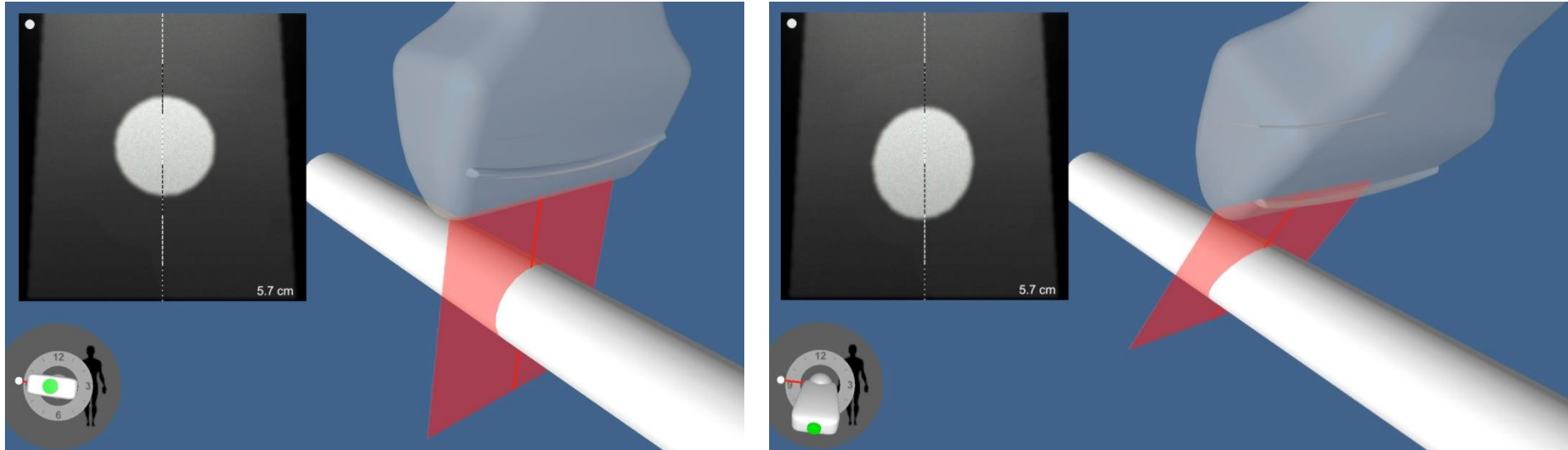
When the structure on US image is oval, it is still possible for the object to be cylindrical, but the insonating plane is cutting it obliquely. Rotation of the probe will prove or disprove this.

As was mentioned, one can rotate the probe over its center axis (here) when nose and heel of the probe move in opposite direction. To move from true short axis to long axis view one must place the structure in the middle of the screen and rotate the probe 90 degree.

One can also stabilize the nose or heel of the probe position and then move the opposite pole if needed.

PARRT probe manipulations

Tilting the probe

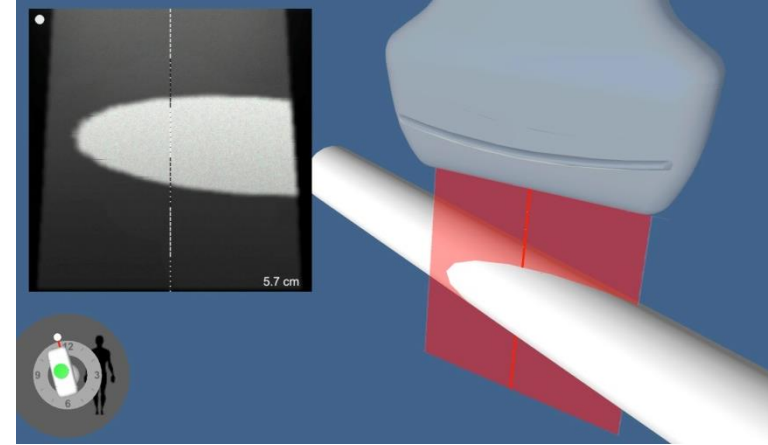
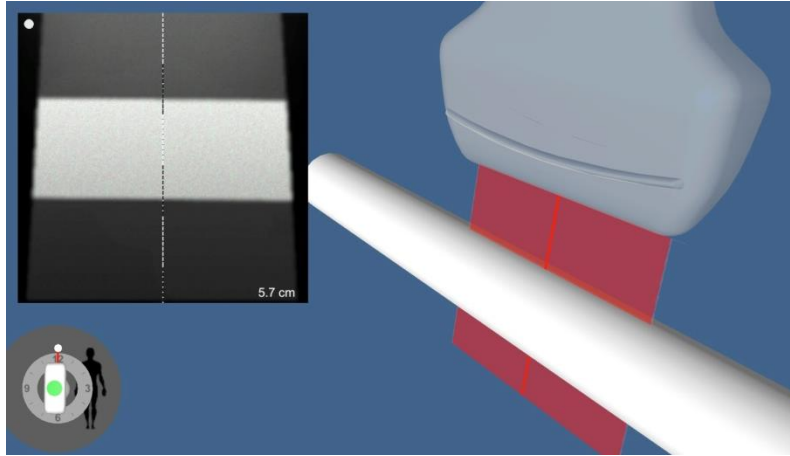


Tilting is a very common and useful maneuver. It helps to “fight negative effects of ultrasound anisotropy” when small changes in angle of incidence translate into big differences in quality of the image (“now you see me and now you don’t” phenomena when the image of a nerve can literally disappear from the screen with slight movements of the probe). When one slides the probe, and the image of the target deteriorates, a small tilt of the probe in either directions could improve the image.


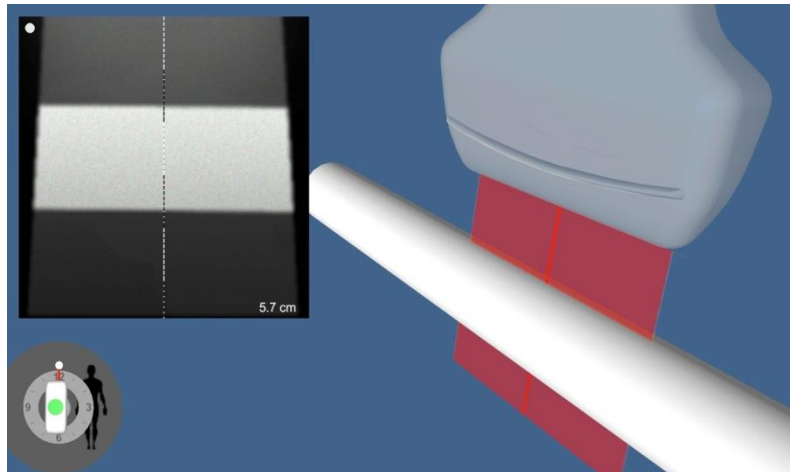
Note the difference in depth and shape of the structure on the US image after the tilt (the image appears more oval and moves deeper). Remember that for better needle visualization with OOP approach, the US beam should be tilted towards the needle (tilting away will make the angle of incidence less favorable).

Some examples of basic probe manipulation and their effects on the image when we dealing with long axis view of a cylinder.

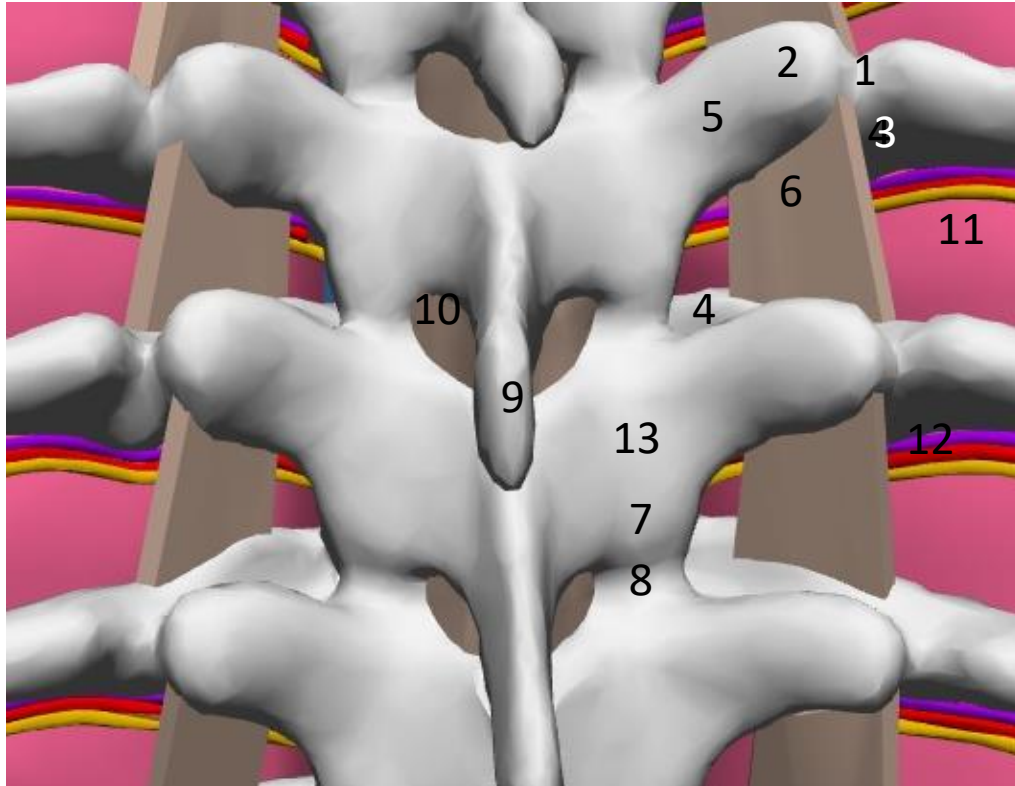
Rotation



Slide off the center axis



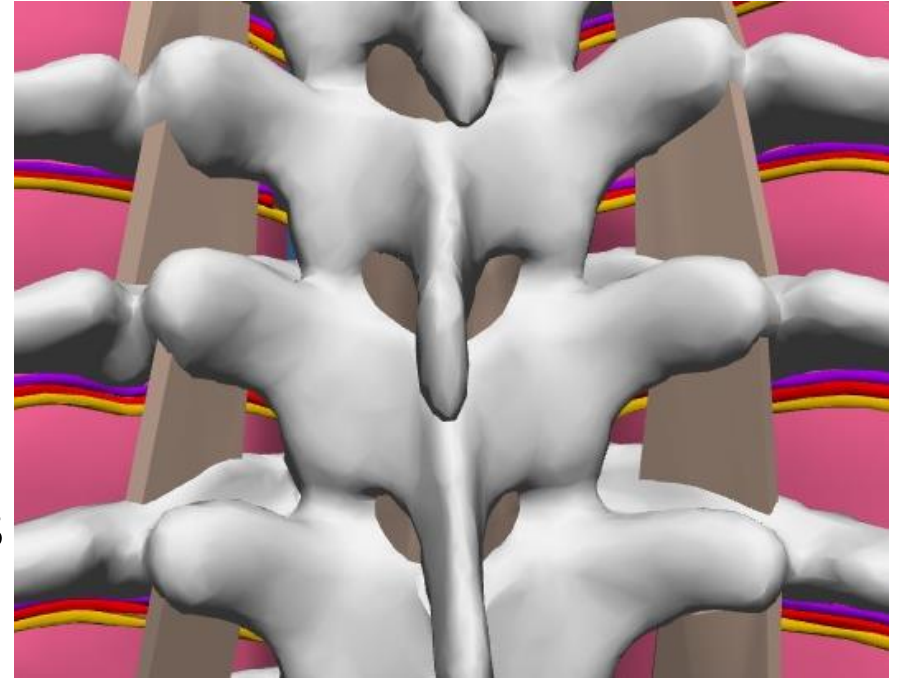
So that we speak the same language, let us review of the basic anatomy before moving on to sono-anatomy.



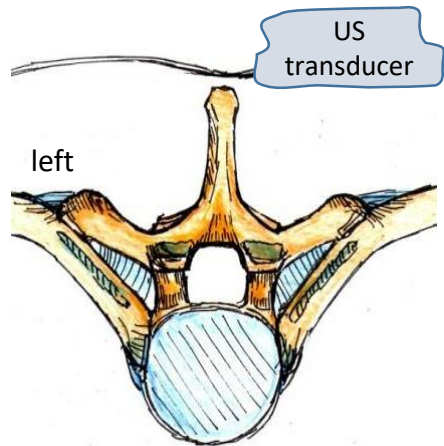
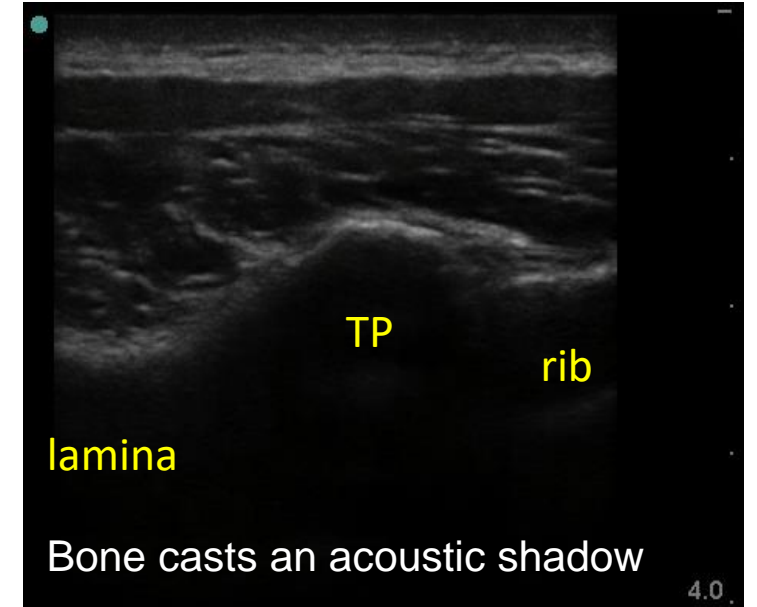
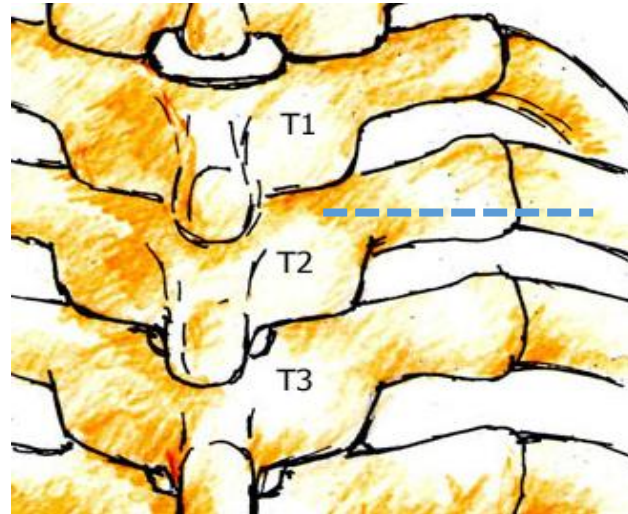
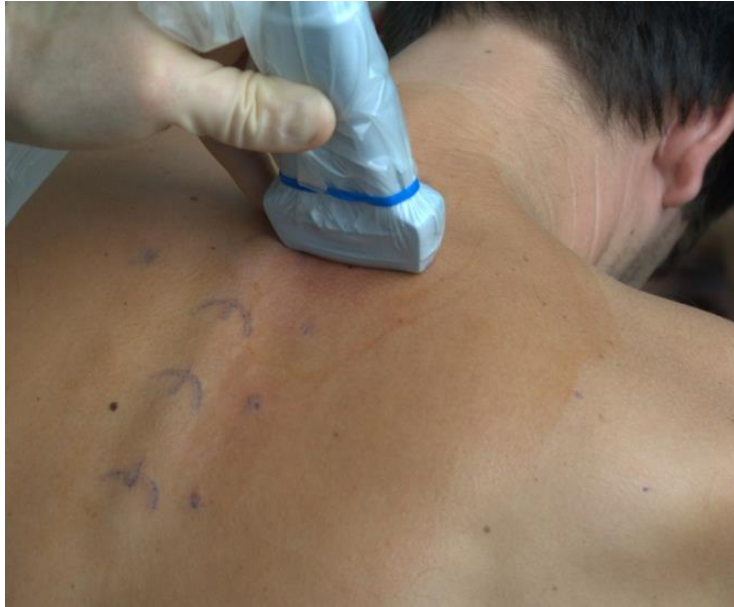1. Costotransverse joint
2. Tip of TP
3. Proximal part of the neck of the rib
4. Head of the rib
5. Root of transverse process (root TP)
6. SCTL
7. Inferior articular process (IAP) of the facet joint
8. Superior articular process (SAP)
9. Spinous process tip
10. Interlaminar space covered by ligamentum flavum
11. Parietal pleura
12. Intercostal vein, artery and nerve
13. Lamina

Review questions

- What is axial and what is sagittal scan?
- Where should the orientation marker be on the US screen? How this is different from TTE?
- When the probe is placed axial, the probe orientation marker should be to the....?
- When the probe is placed sagittal, the probe orientation marker should be to the....?
- What happens if the probe orientation marker is pointing in a wrong direction?
- Can you point the following structures on the picture: root of TP, tip of TP, CT junction, IAP, head of the rib

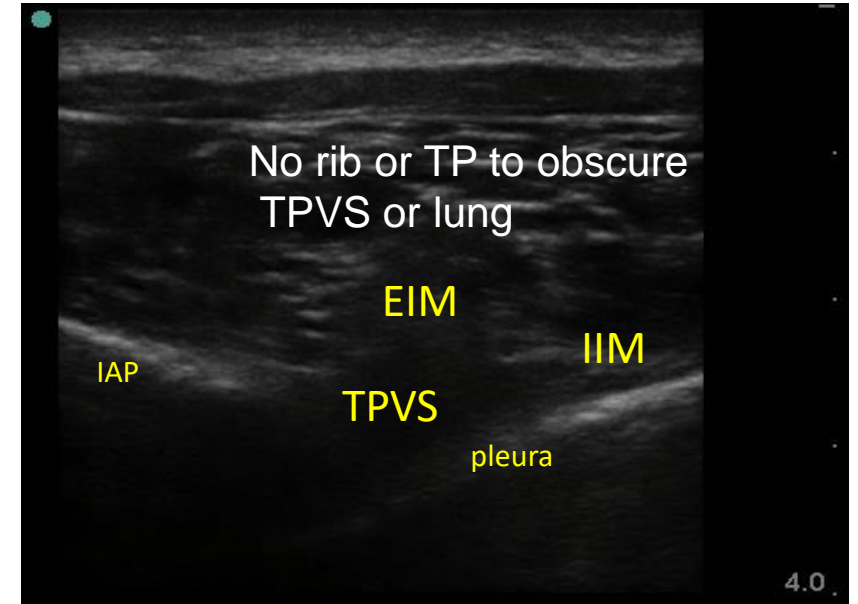
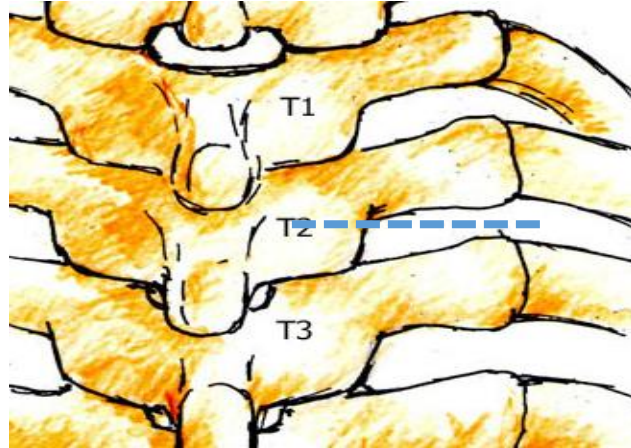
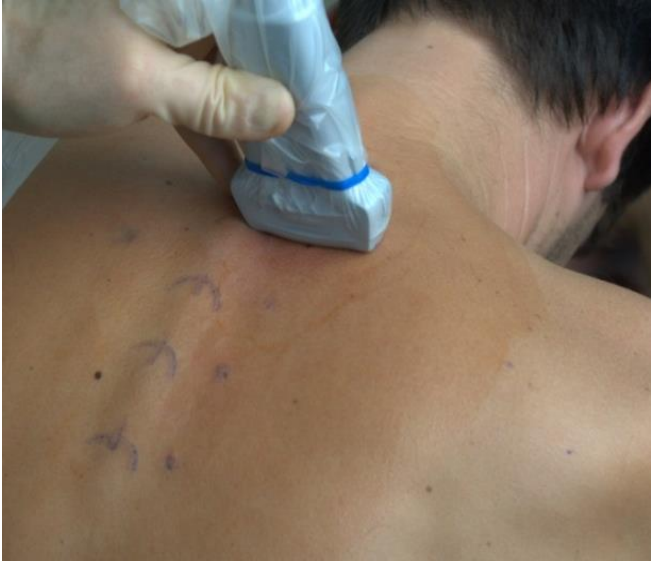

Sonoanatomy of TPVB: Axial scan over costotransverse junction (blue dashed line on the sketch)



The ultrasound probe is positioned at the same level as the blue line on the skeleton sketch

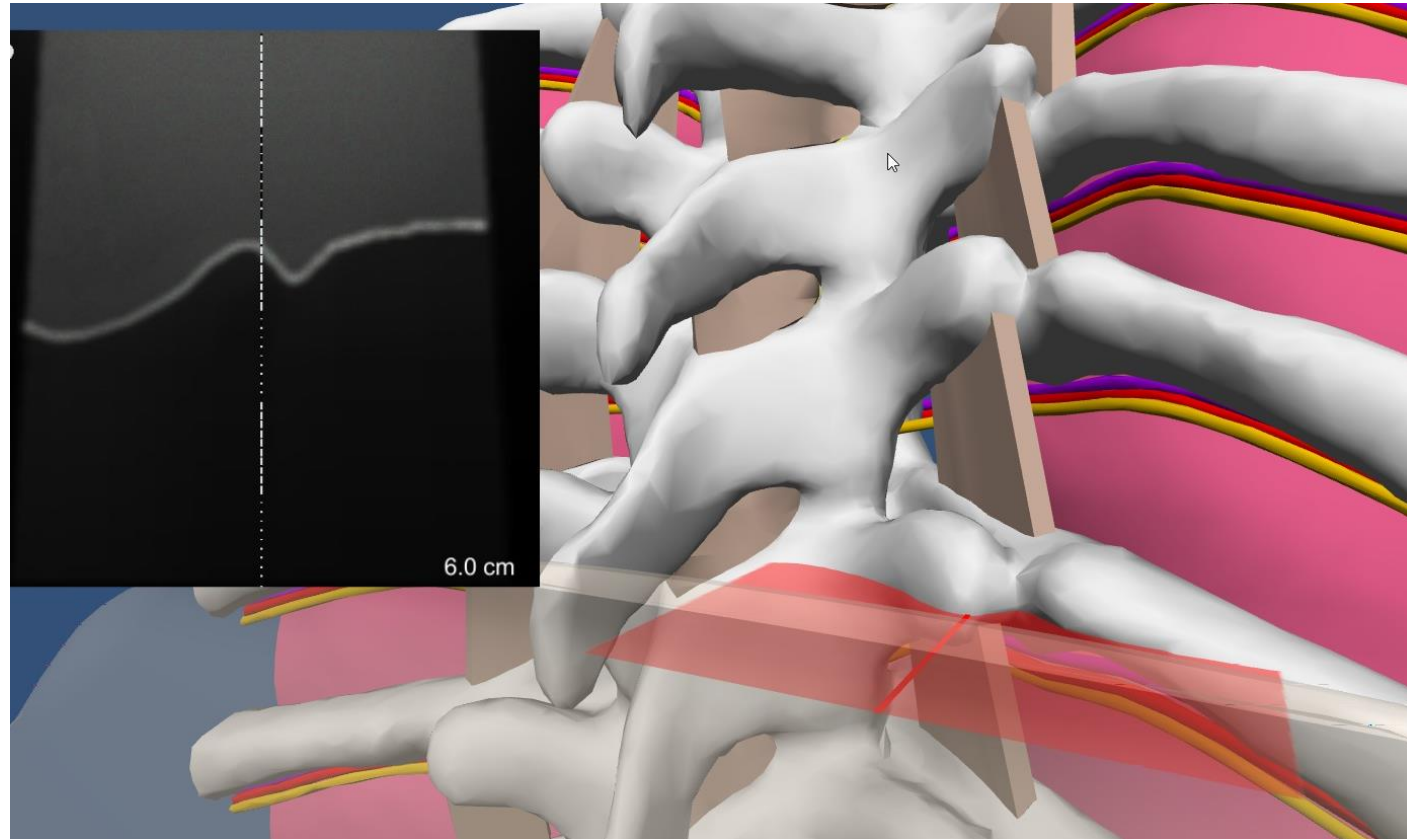
Sonoanatomy for TPVB. Axial scan over TPVS: between TPs and ribs, IAP medially
(blue dashed line on the sketch)



Tilt or slide the probe caudally to “move” the US beam caudad to and off of the TP or rib

The ultrasound probe is positioned at the same level as the blue line on the skeleton sketch (between TPs and ribs).
IIM-internal intercostal membrane, EIM-external intercostal muscle, IAP-inferior articular process

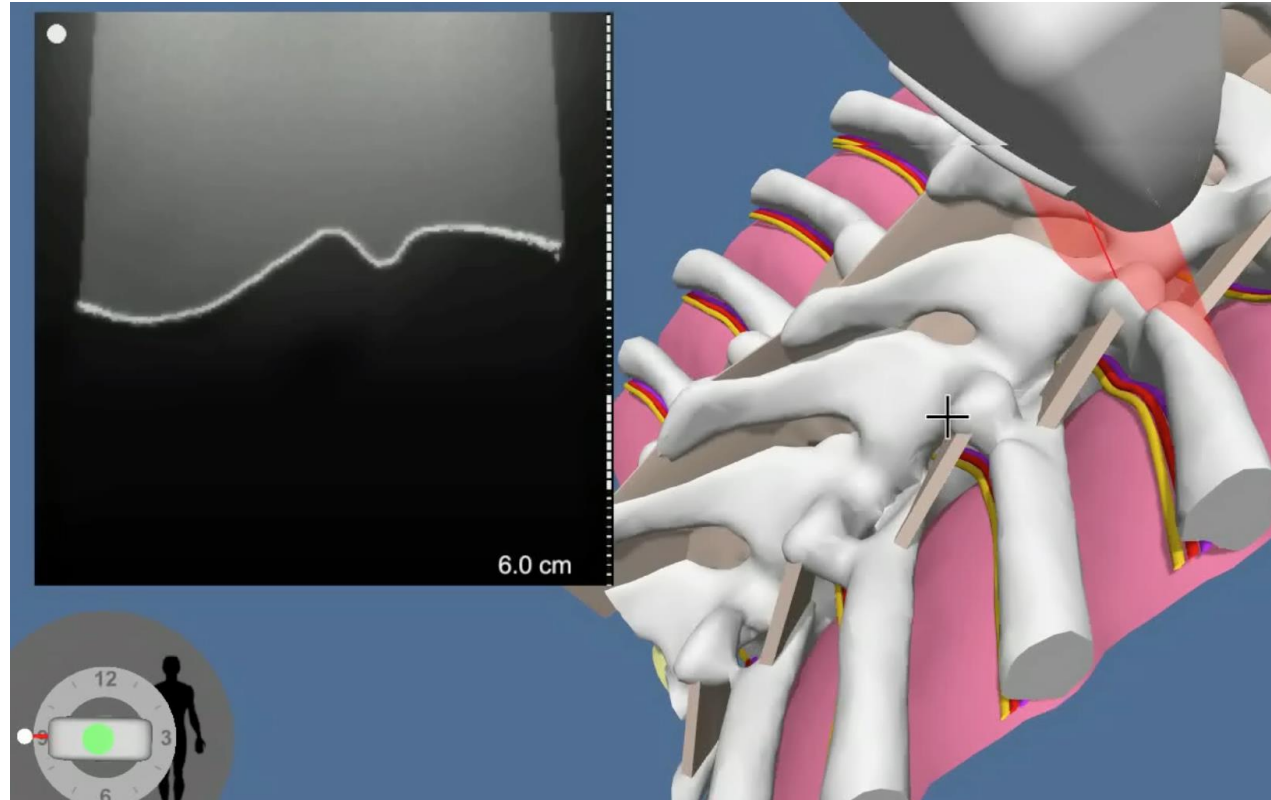
Sonoanatomy on the simulator



On our simulator, the US beam is shown as the semi-translucent red rectangle on the colored diagram. The virtual US image acquired, in black and white, is on the upper left corner. If we follow the interface of virtual US beam and anatomical structures (muscles excluded) we will go over the line of bone on that image, from medial to lateral, we will see: lamina-root of TP-tip of TP-costotransverse junction-rib.

We will cover more details of standard and non-standard axial US views on the next several slides

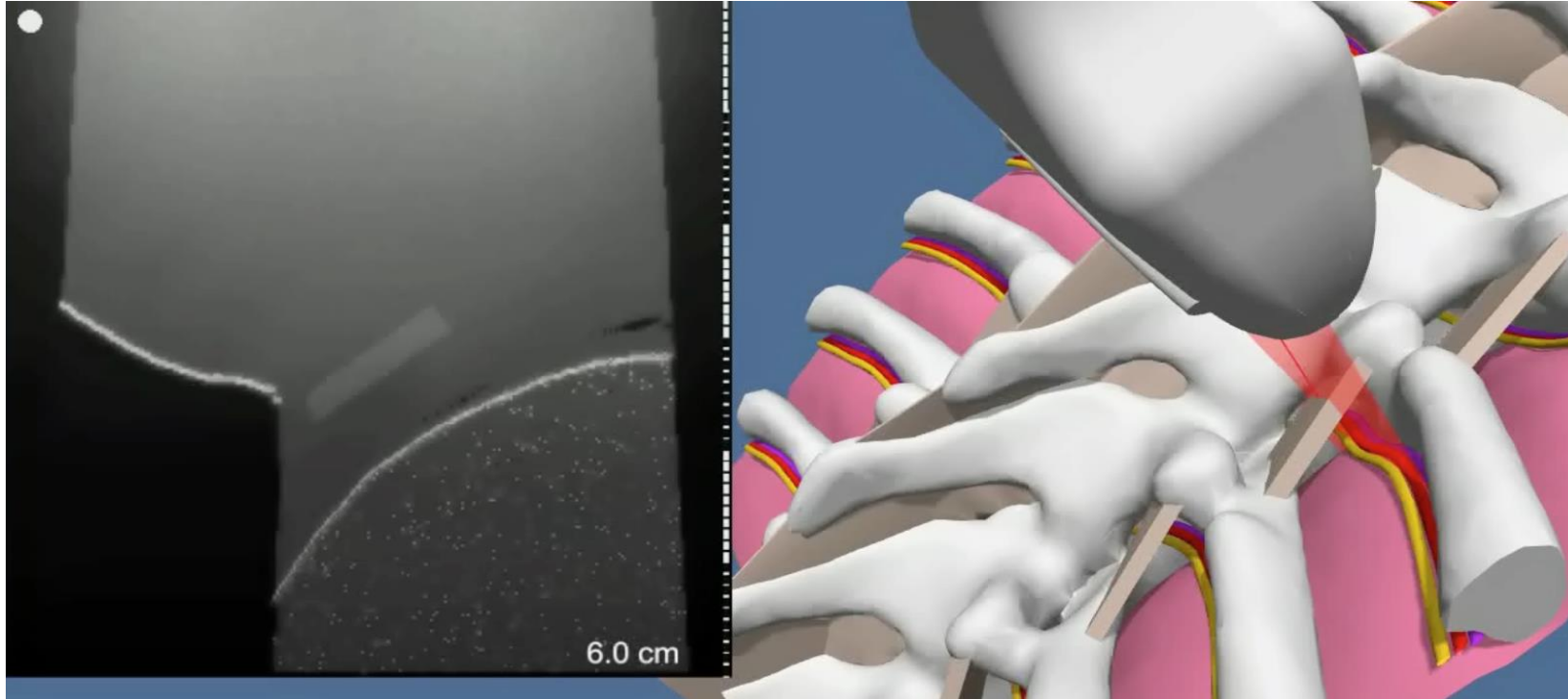
Standard axial view of TP (probe is perpendicular)



Standard axial view of the TP: This view is used to mark the tip of the TP projection on the skin. This view is also used to obtain a standard axial view of the TPVS by sliding the probe slightly down

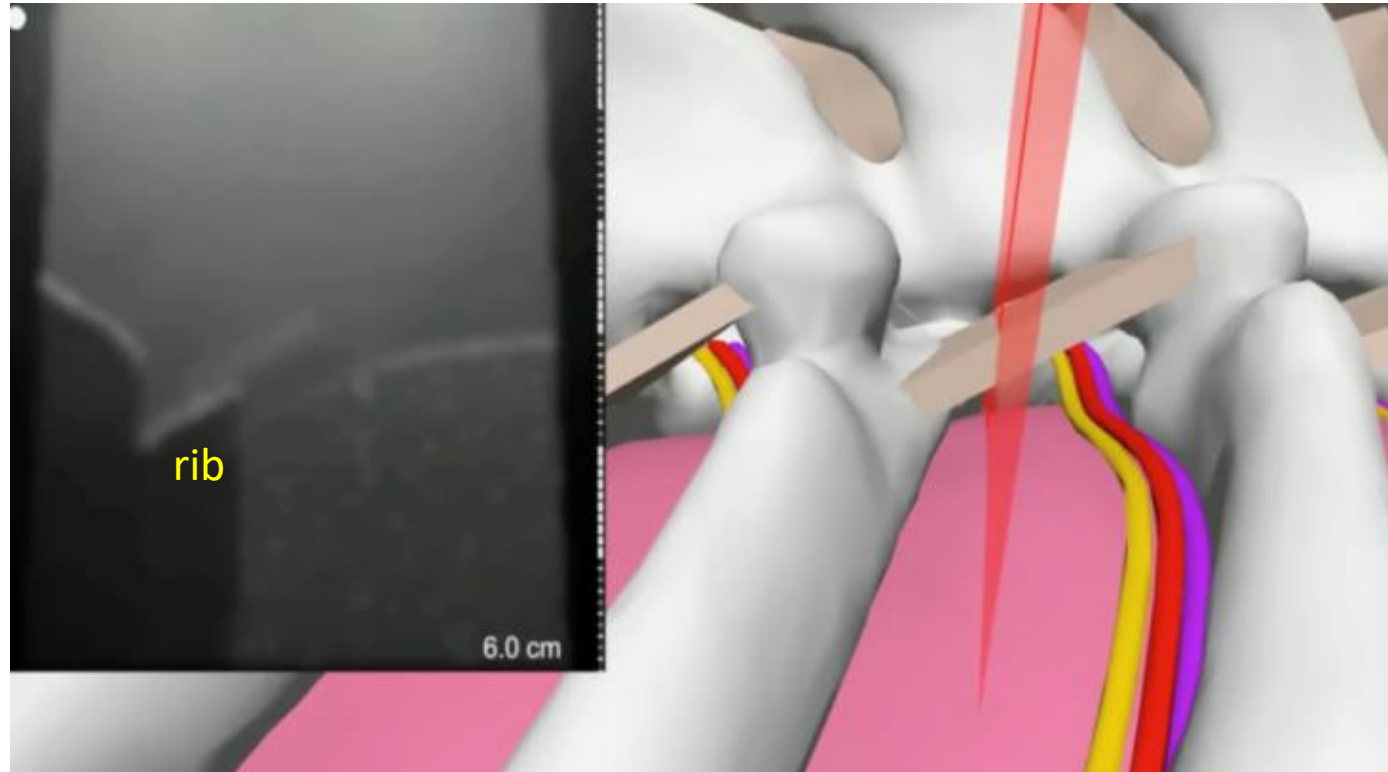
- **The probe is correctly oriented**
- **The probe is not rotated, tilted or rocked (pay attention to the probe position to the surface indicator on the lower left)**
- **The TP tip is in the middle of the image**
- **The US beam hits the TP at its most prominent (superficial) point**

Standard axial view of TPVS (just below TP)




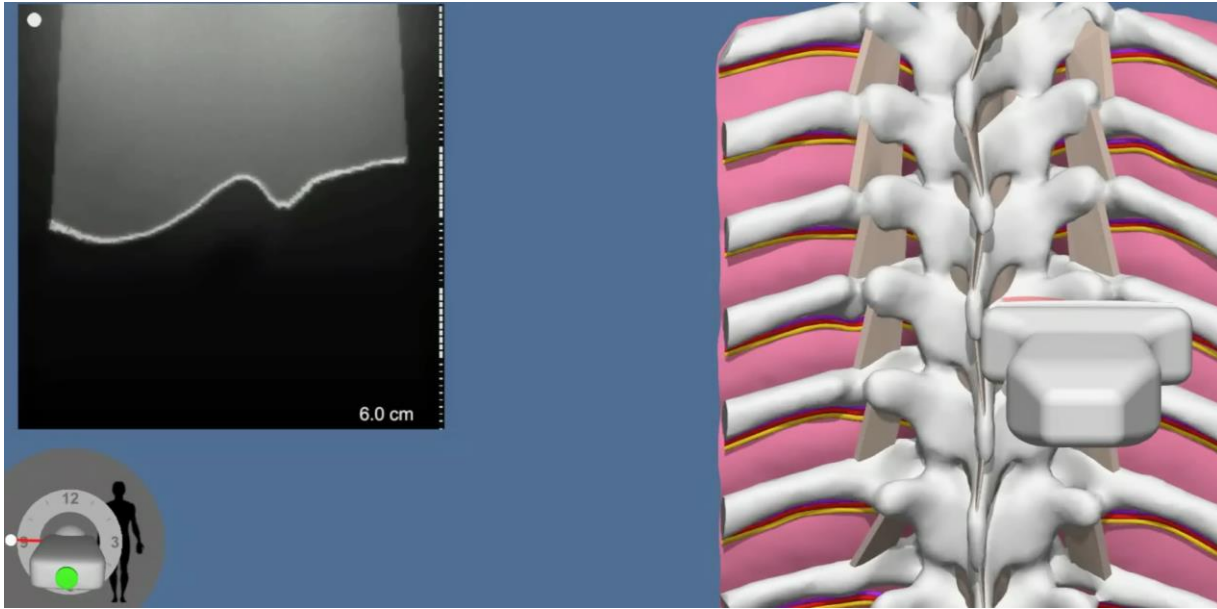
- The probe is correctly oriented, not rotated, tilted or rocked
- The US beam, a few mm below the TP and the rib, cuts the TPVS in its cranial third (that is wider than the lower third which is closer to the rib below)
- This view is usually obtained from the standard axial view of the TP by sliding the probe slightly downward. In this view, the probe is positioned right over the future needle entry point for US assisted technique
- This view is used for measuring the depth to the lung and calculating “delta”. This view is also used to obtain a modified axial view of the TP
- The standard axial view of the TPVS is slightly modified for the US guided technique (more details to come, but in short, the probe is moved laterally and rocked towards the patient’s midline)

TPVS axial view in its lower (caudad) third that is closer to rib below



- Note on the medial side of the image the shadow of the head of the rib below (just lateral to the lower part of the IAP)
- Note that the AP dimension of the TPVS is slightly less here than in the cranial part of the TPVS

Modified standard axial view of TP (probe tilted up)

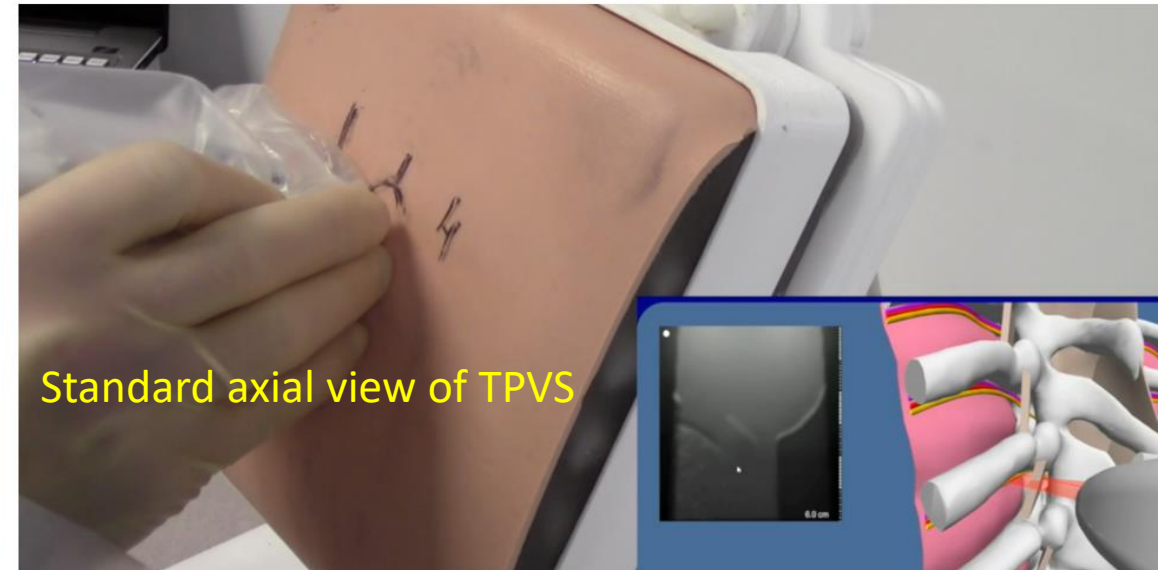


This view, although it looks the same as the standard axial view of the TP, it is derived from the standard axial view of the TPVS by slightly tilting the probe up.

Pay attention to the cognitive aid in the lower left corner- this aid reflects the US transducer's perpendicularity to the surface.

This view is used to measure the distance to the TP from the needle entry point and then for the calculation of Delta.

Avoid excessive soft tissue compression when measuring the depth

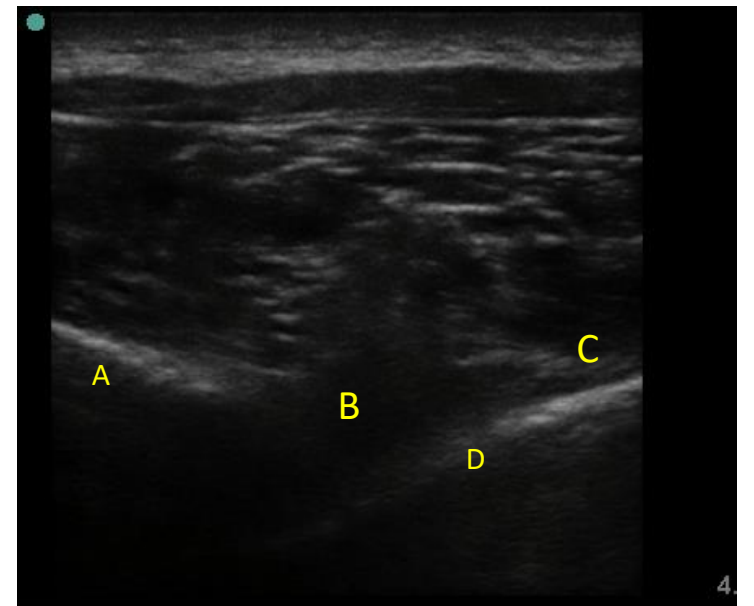
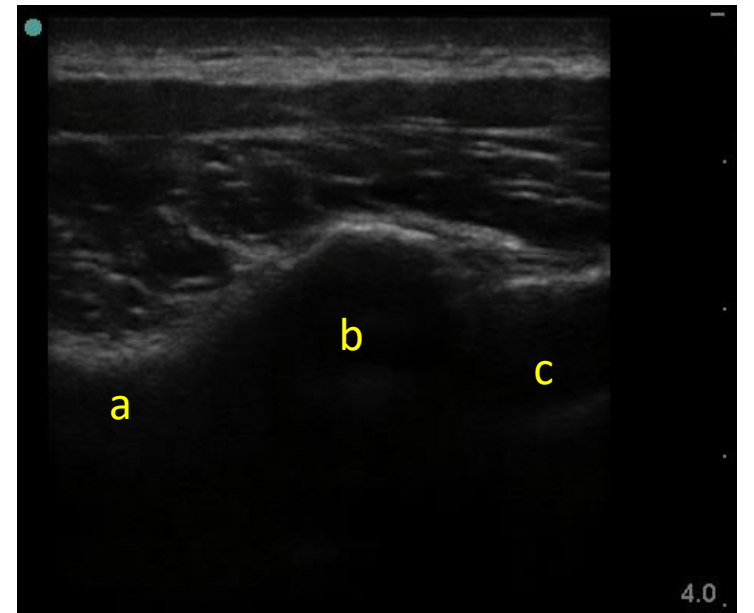


Review questions

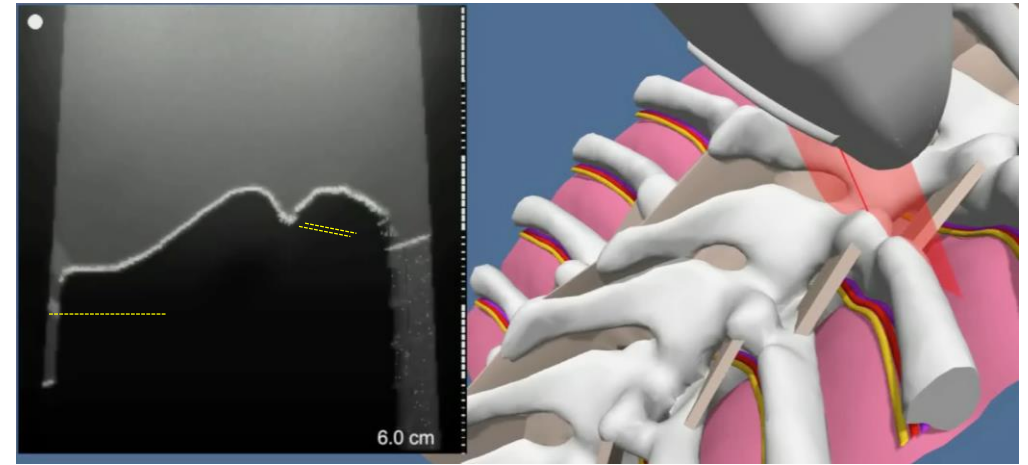
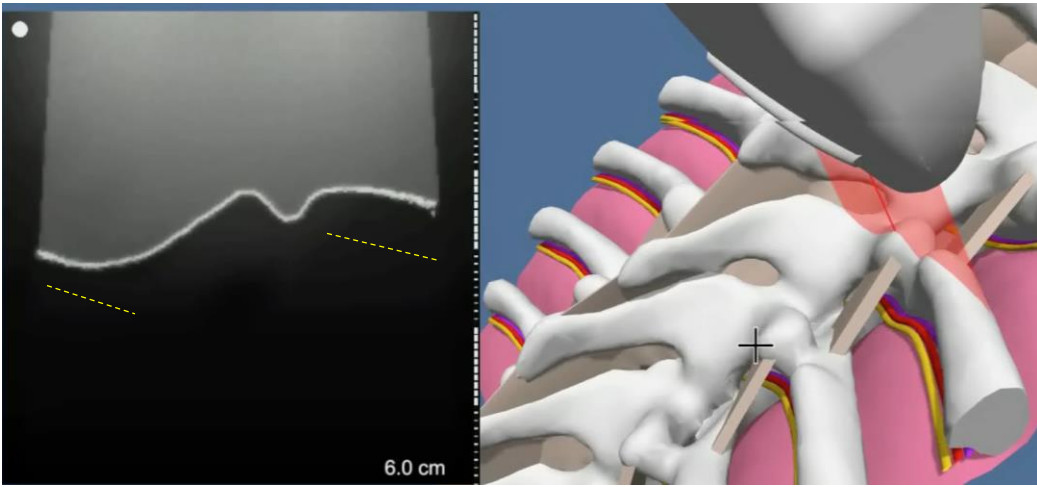
- Can you visualize in your mind the standard axial US image of TP?
- What are the 4 requirements for the optimal standard image?
- Can you visualize the standard axial view of TPVS, what are the requirements?
- Explain the difference of the modified axial view of TP from the standard view?

Review questions

- Name the anatomical structures labeled on the images to the right.



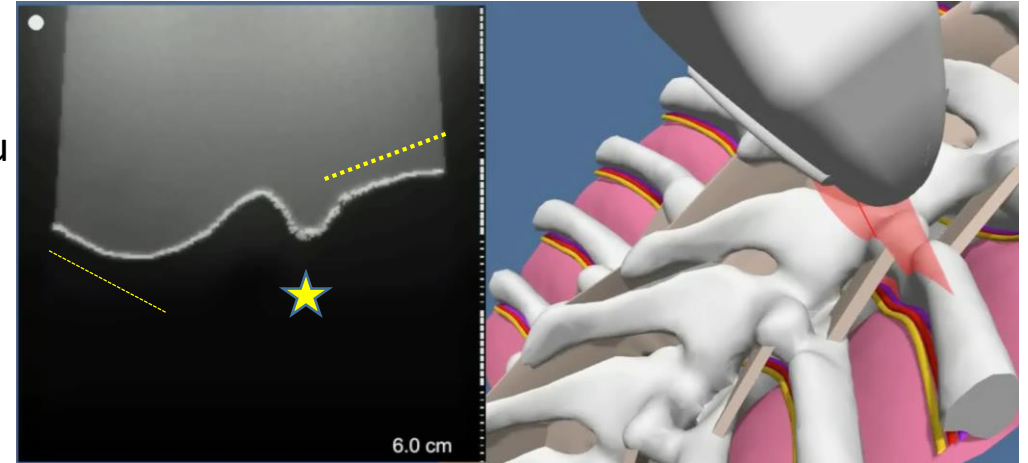
Images from the
close by areas
(imposters)



Compare standard axial view of TP (above) with some other images of the area close by (3 images on the right)

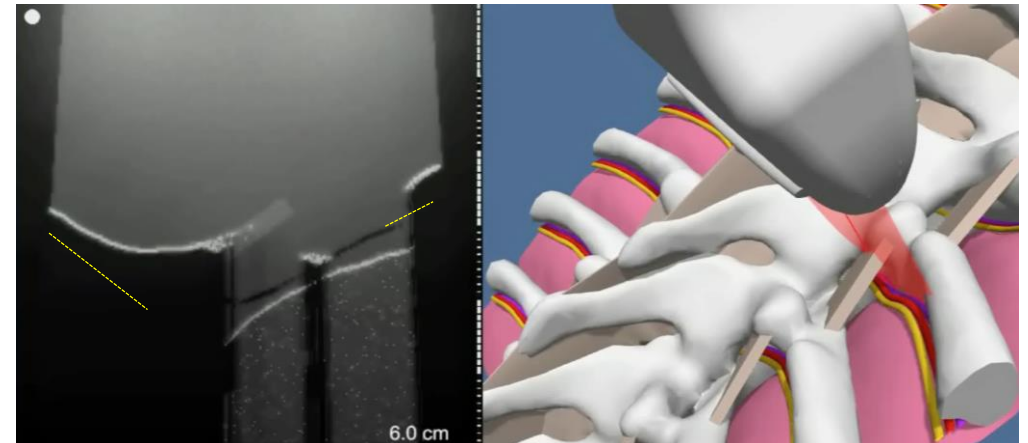
Knowing small differences at the different levels around the TP tip will help you to get a correct standard image more quickly

The top right image shows the scan that is slightly **too cranial**: note how the bony shadow medially does not go up (SAP area) and how we gradually lose the rib outline on the lateral part of the US image



On the middle image (slightly **too caudal** from the ideal position) we can see a much more prominent step up medially and an accentuated dip at the costotransverse junction (star) with the rib outline pointed up (oblique cut from deep to superficial- on the standard image, the rib outline goes down: from superficial to deep)

On the lower image (**even more caudad**) we are missing bony structures in the middle.



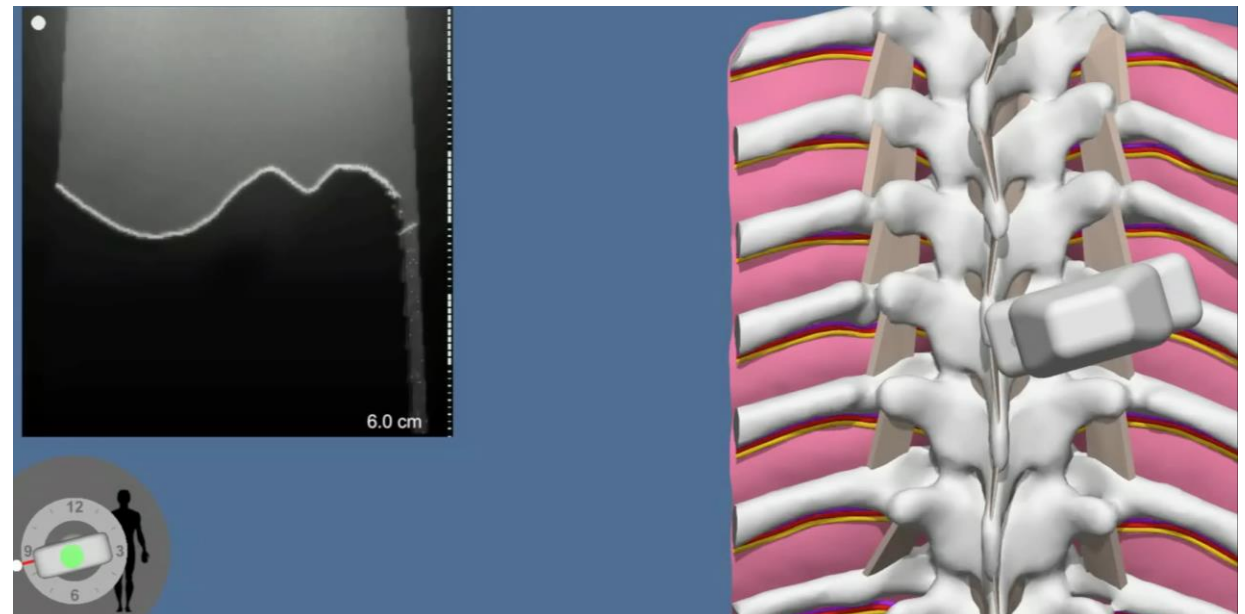
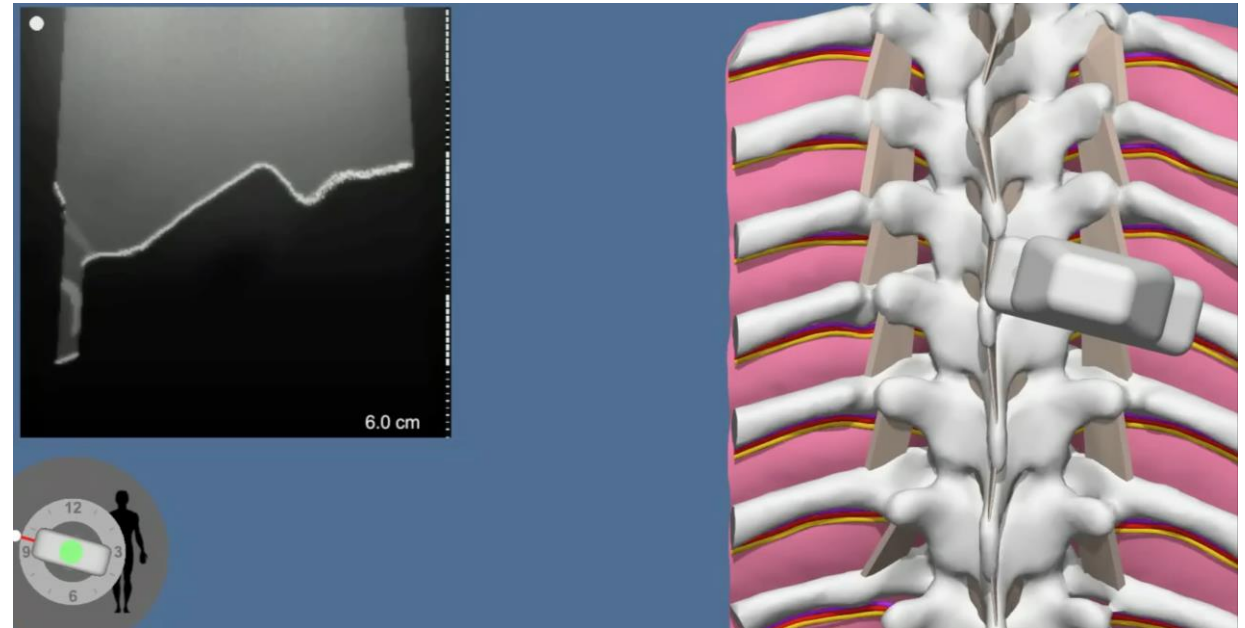
Probe rotations (clock and counter clockwise)

When the probe is inadvertently rotated we can notice this on the image. When we get this image it is more or less a hybrid image: the medial part of the image is higher than the ideal level and the lateral part of the image is lower than ideal (example shown on the top right)

On the bottom right we see the opposite: the medial part of the image is lower than the ideal cut and the lateral part is a higher than ideal cut.

Multiple variations are possible.

It is a good habit to have to look back at the probe and make sure it is not rotated inadvertently

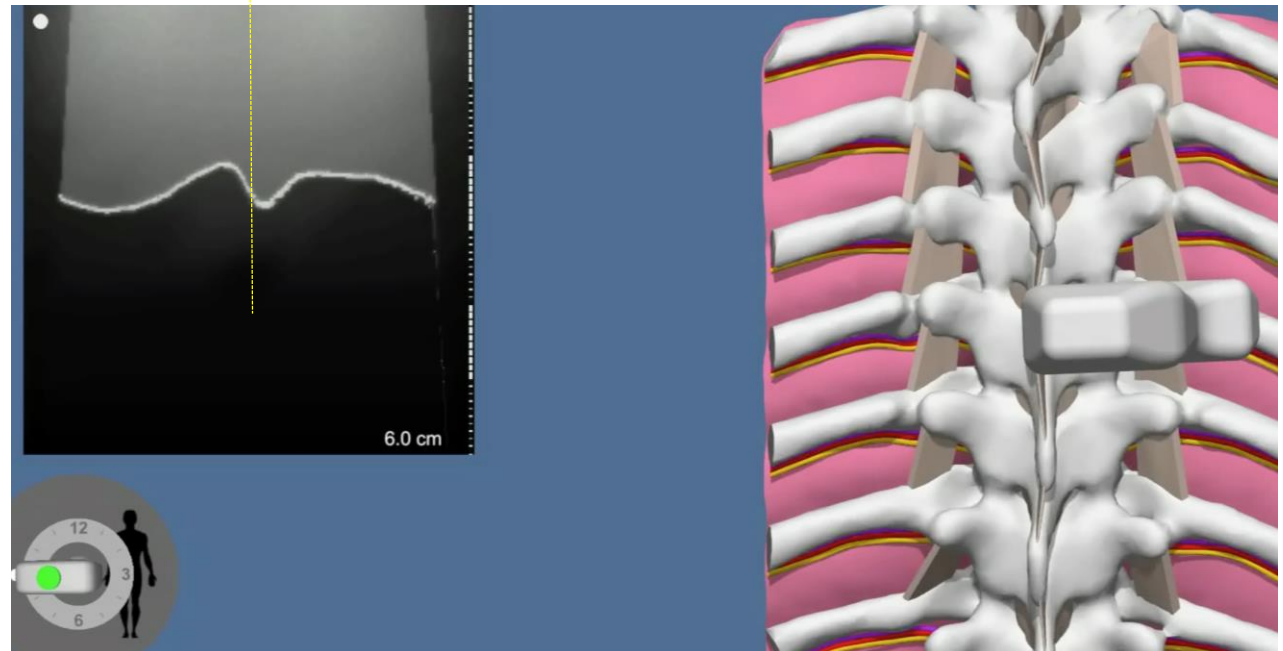
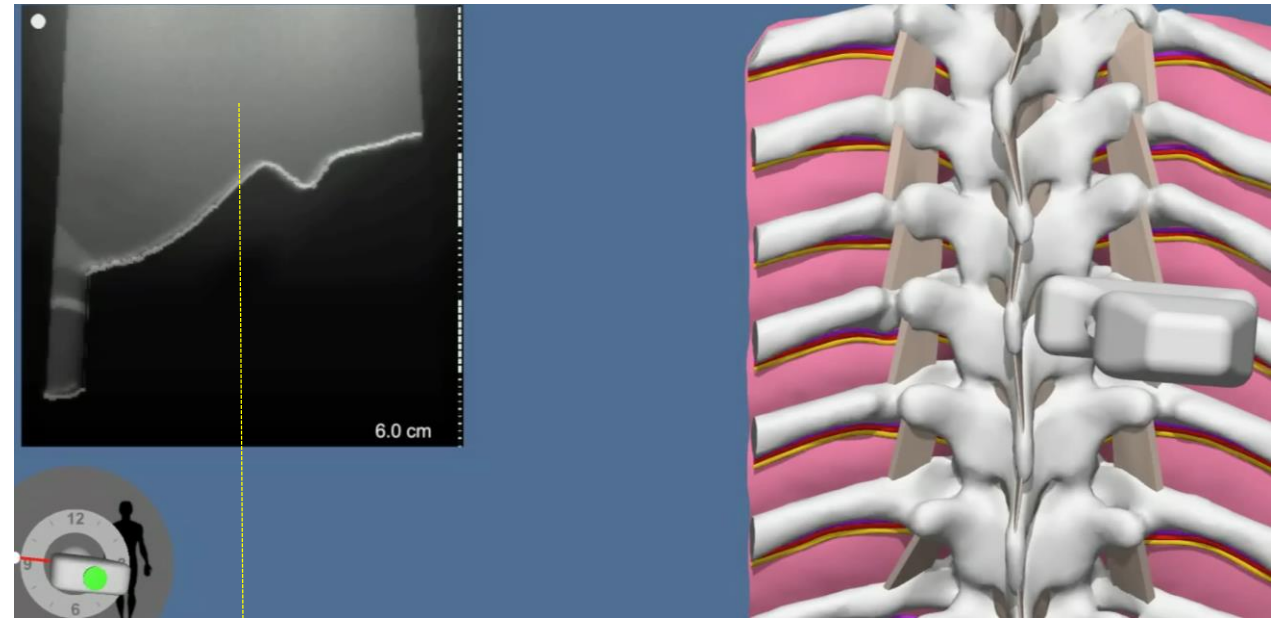


Rocking the probe in axial position

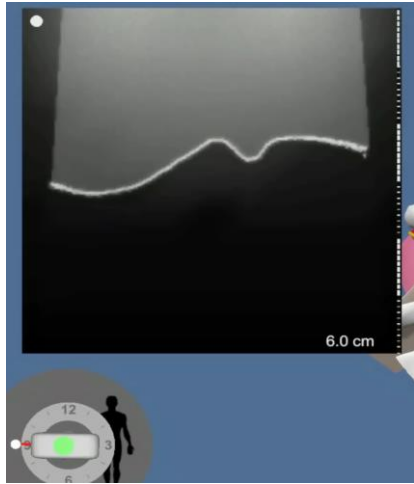
When we apply more pressure on one side of the probe, (medial or lateral in relation to the patient) the probe rocks. On the image, the typical depth to the structure on the side of the pressure is decreased.

It is more important to notice when the probe is rocked, as the midline structure (in this case- the tip of TP) is shifted. This may lead to an incorrect marking of the skin projection of the midline structure.

Note: the examples at the right represent the tip of the TP **more medial during applying more pressure on medial side of the probe** and **more lateral during applying more pressure on the lateral side of the probe**



Effect of tilting the probe (cranial or caudad)

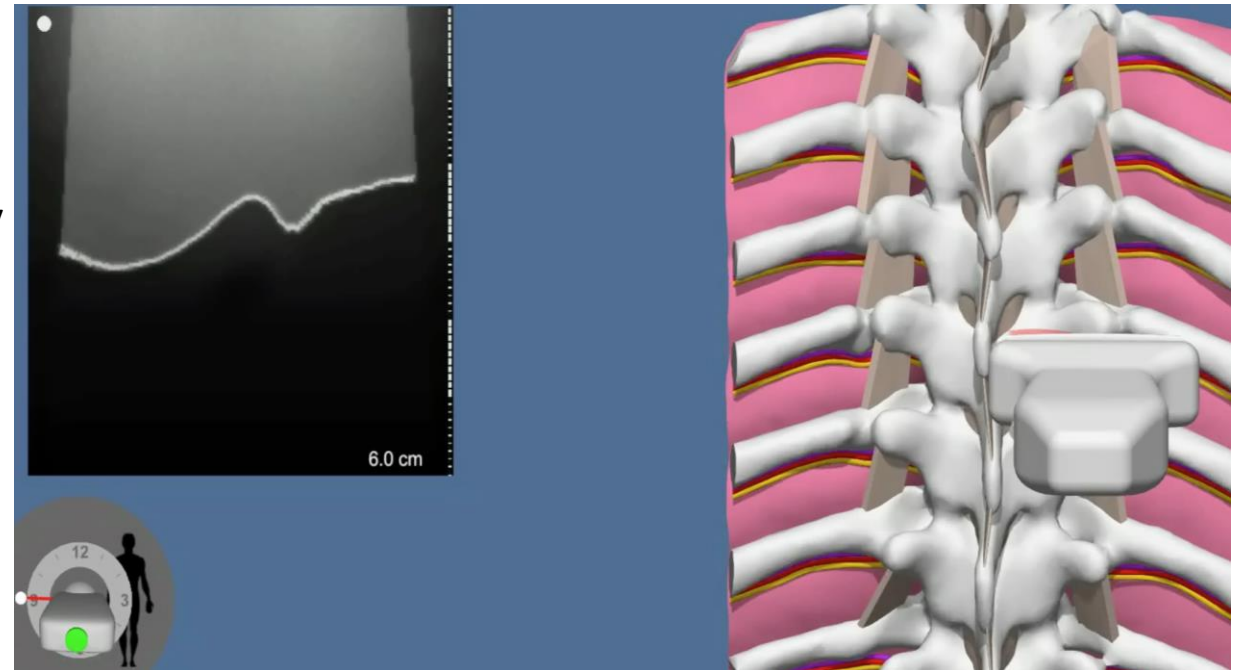
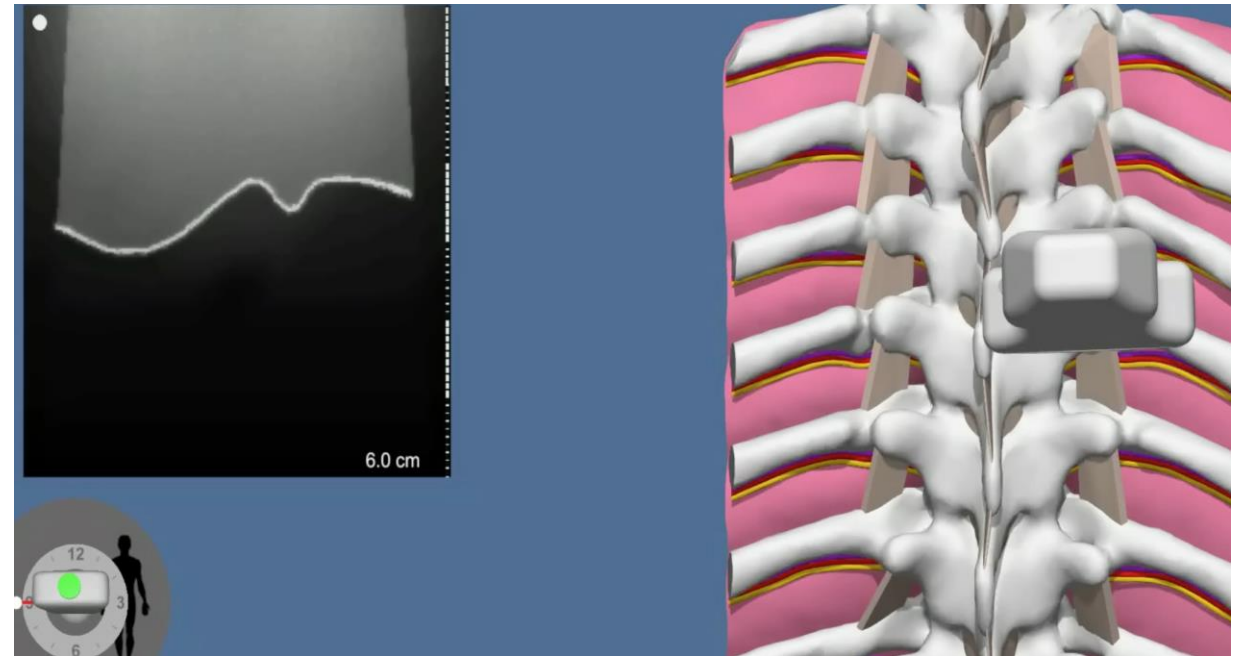


If the US beam cuts through similar structures, it is difficult to see the difference between the image that is taken with the probe perpendicular to all planes (on the left) vs the image that is taken when the probe is tilted down (top right) or up (lower right)-slight difference on the rib outline.


Pay attention to the indicator of the US transducers perpendicularity to the surface in the lower left corner.

Theoretically, the image taken with the probe tilted should show a higher depth to the TP. In reality, this is not clinically significant if the degree of the tilt is mild. **Our correct eye level is crucial for the ability to notice the tilt when the probe is axial.**

It is a good habit to regularly [switch your attention from the US screen to the probe to make sure you are not tilting, rotating or rocking the probe.](#)



Importance of placing tip of TP in the middle of the image and marking the middle of the probe



On the left slide the tip of the TP is in the middle of the image. If we are accurate and mark the skin at the middle of the probe, we will have an accurate skin projection of the tip of TP in axial plane.







Imagine the situation when one is sloppy in placing tip of TP in the middle of the screen and tip of TP is slightly medial to the correct position (right image), or imagine that one marked the probe slightly lateral to its true middle. In both situations we may end up with a skin mark that is over the “dip” of the costotransverse junction. Note (depth marks are on the right of the image) that depth of the bone there is 5 mm more. If one does not recognize that error and advance the needle to a “standard predetermine distance of 1 cm past TP” there is a real risk of the pleura injury. (yellow, red, and orange lines are all 1 cm on the image to the right, orange line cross the pleura!)

One should be very diligent in 1. obtaining the correct image of TP, 2. correct position of TP in the middle of the US screen, 3. marking the skin at the middle of the probe, 4. advancing the needle perpendicular to all planes 5. Also remember to check the depth at which you hit the os (is it as expected?) All these should help to avoid lung injury

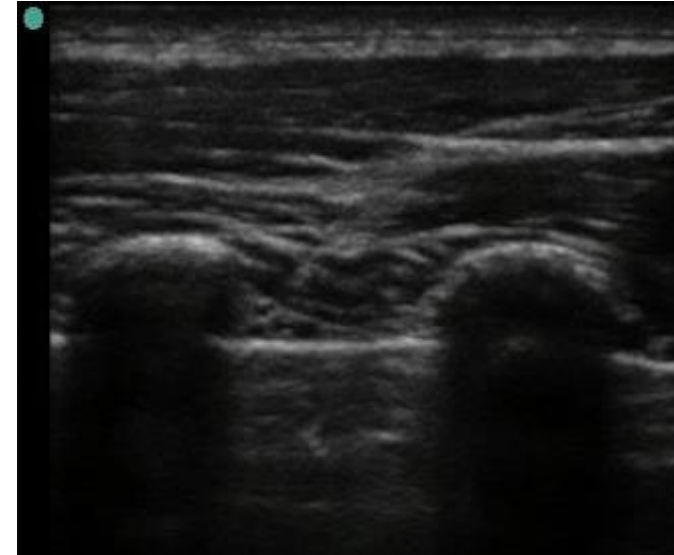
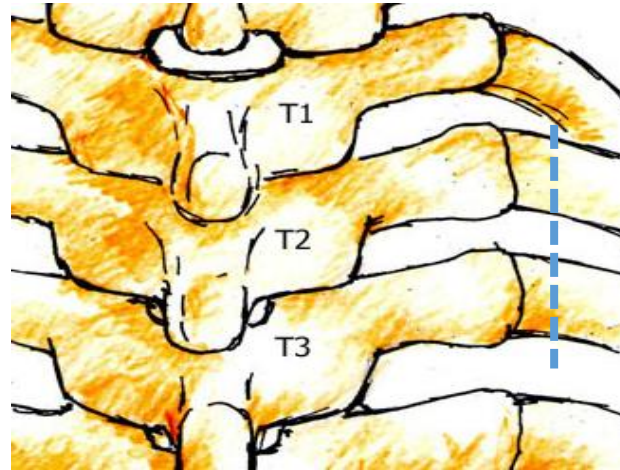
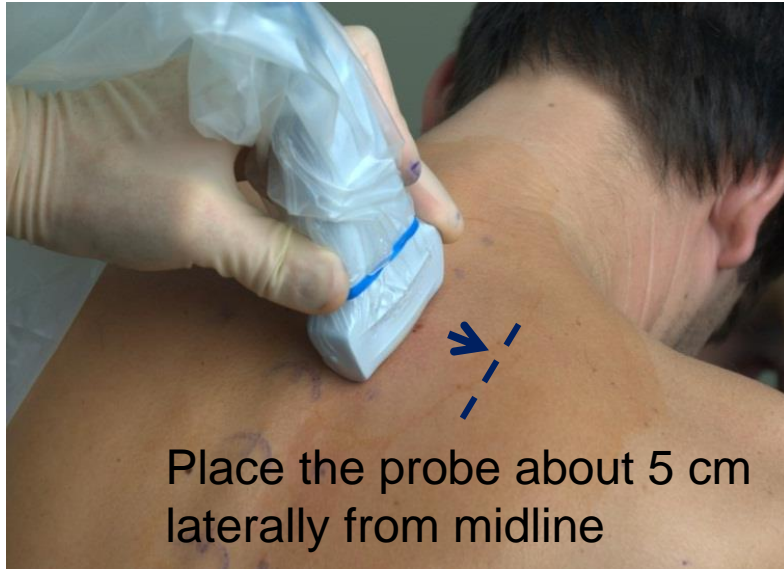It is best to be accurate, but If one should make a mistake in marking, it would be better to mark slightly more medially than the true tip of TP -red 1 cm line on the image (lung is getting deeper medially)

Review questions

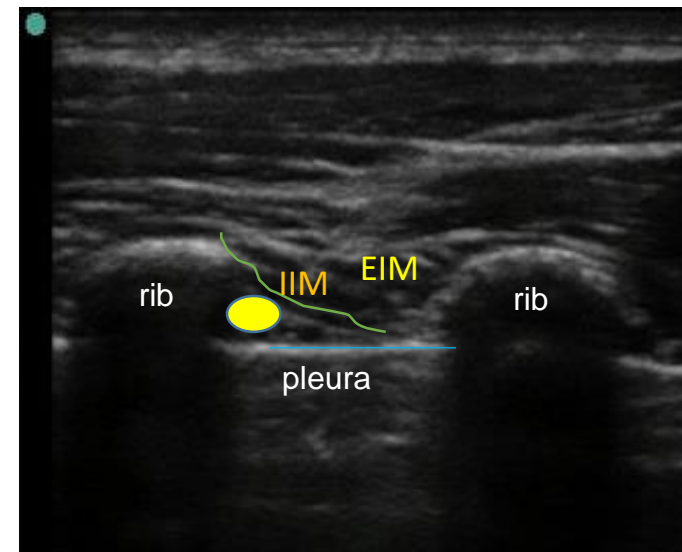
- Explain the differences in images (vertical slide and rotation)
- Explain how rocking the probe affects the axial image
- Explain how tilting the probe affect the axial image
- Explain how one can inadvertently mark the projection of TP more lateral than it is actually located and why it is dangerous



Sagittal scans for TPVB paramedian sagittal scan over ribs

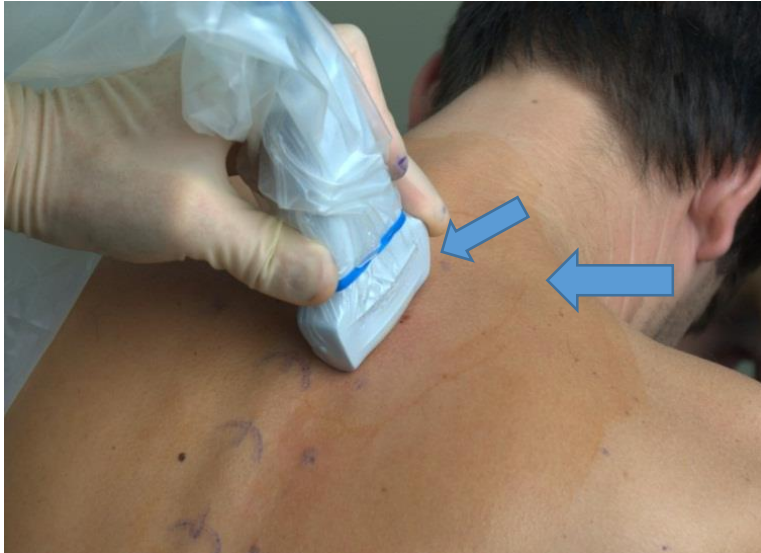

The probe is placed in the sagittal (longitudinal) plane as demonstrated by the blue dashed line on the skeleton sketch

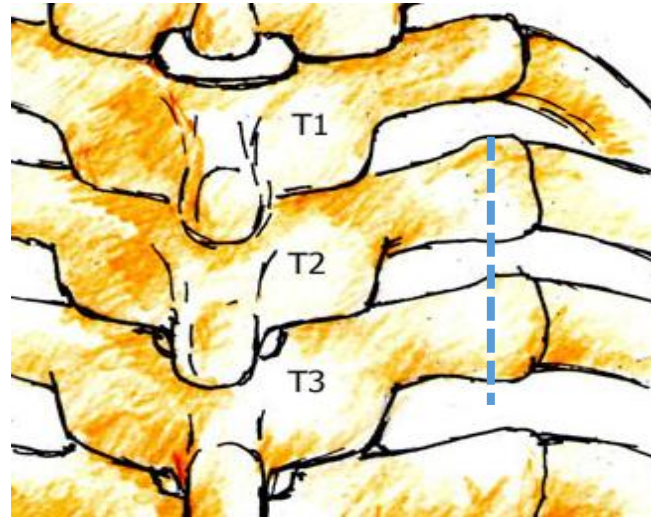


Sagittal scans (continued)

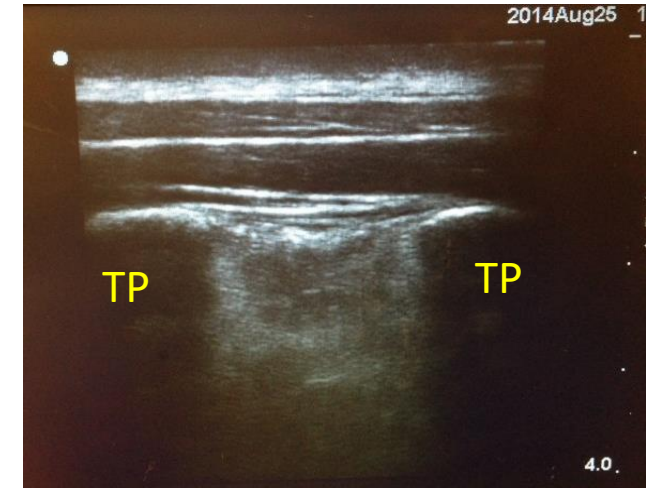
Scan over tip of TP-no probe tilt, and
Scan over TP tip with slight lateral tilt



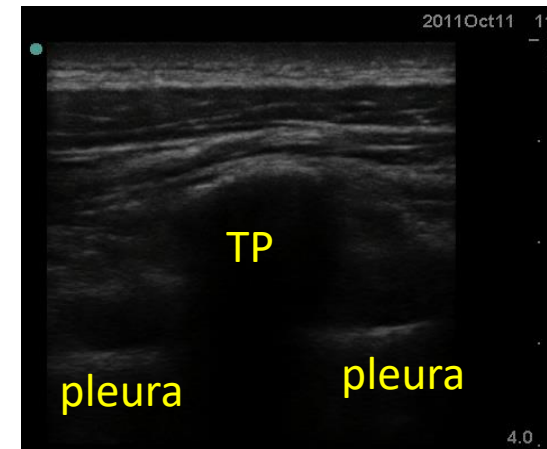
- 1) Start about 5cm laterally from midline and slide the probe medially from “rib only” view (previous slide Sagittal over rib) until you see TPs (about 2.5-3 cm from midline), Observe the step up at the rib-TP interface. Note the more squared shape of TP compared to the rounder rib
- 2) In order to see the lung better, slide the probe a bit more medially and tilt the probe slightly laterally until you see the lung.
If you overtilt laterally, you will get the “ribs only” view



The probe is placed about 2.5-3 cm from midline in the sagittal (longitudinal) plane over the tip of TP as demonstrated by the blue dashed line on the skeleton

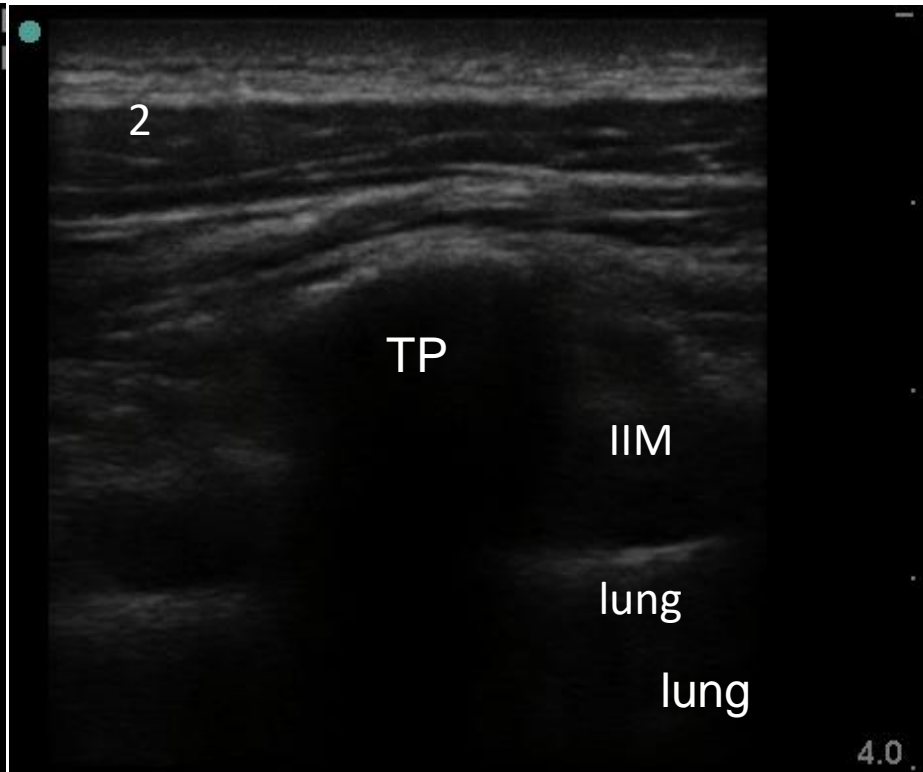
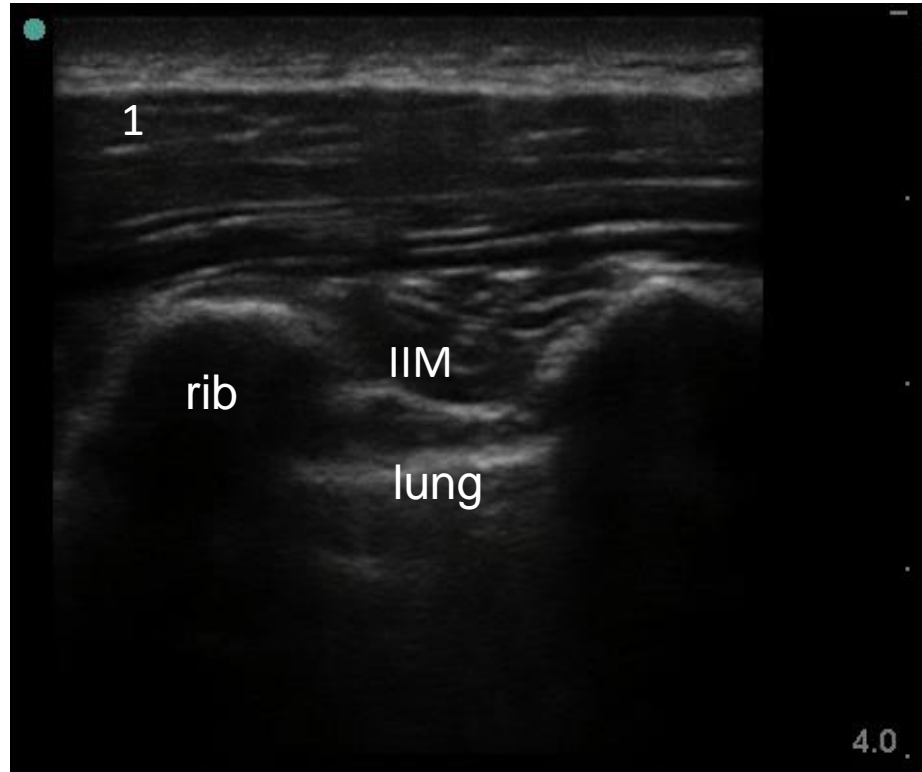
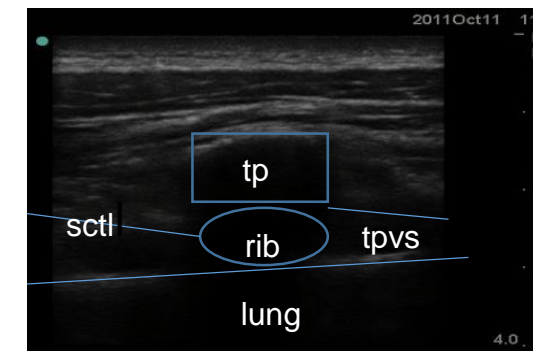
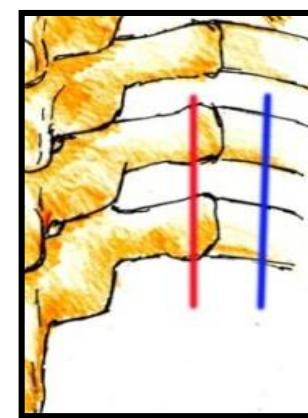


Scan 2a- no tilt, sagittal: one can clearly see 2 TP on the sides of the screen, but pleura line is unclear



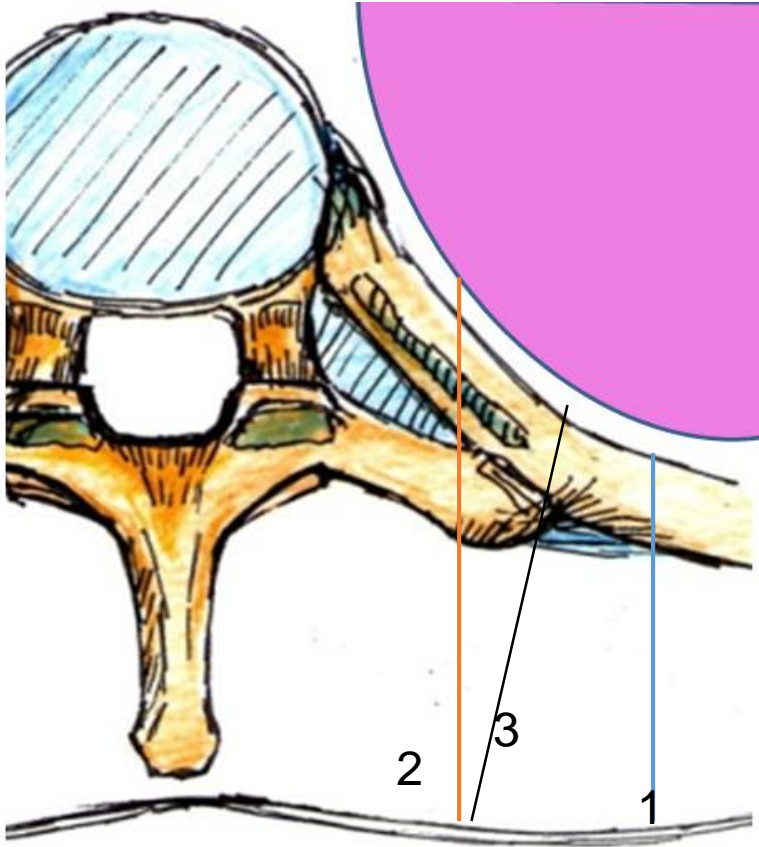
2b-sagittal with slight lateral tilt: in order to delineate the lung, the TP is positioned in the middle of this US image

Transition from Sagittal scan over ribs (blue line on the sketch) to Sagittal scan over TP tip (red line on the sketch)



As the probe moves from lateral to medial, the round rib outline is replaced by a squarer TP outline. Note the slightly shallower depth of TP compared to rib. Medially, the rib is completely overshadowed by the TP. The lung reflection becomes deeper. The space between internal intercostal membrane (IIM) and the parietal pleura widens.

Why does one occasionally need to tilt US probe (beam) laterally to see the lung better?

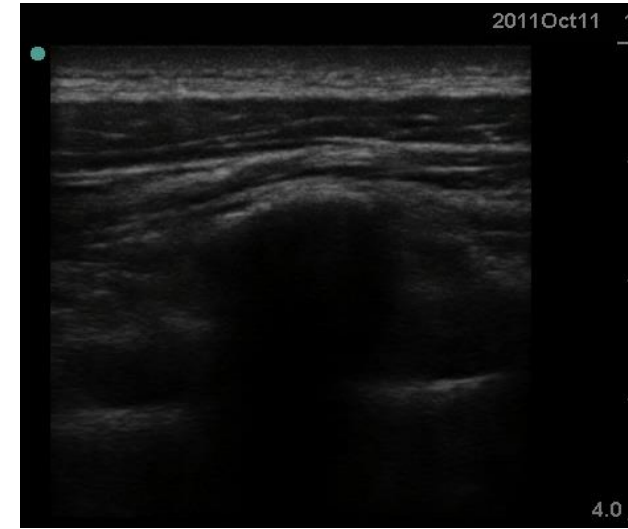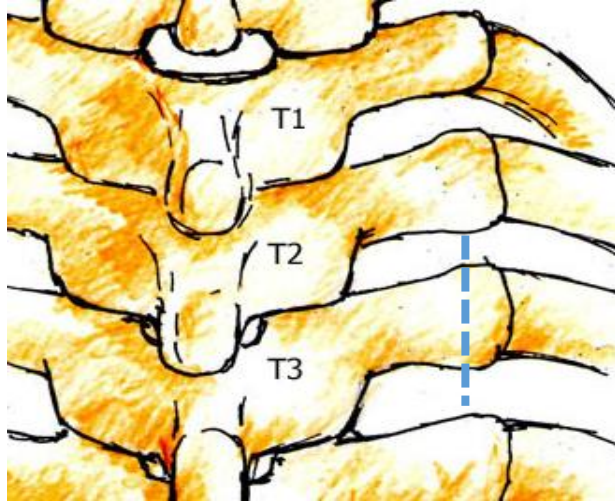


US beam directions with different angles of incidence

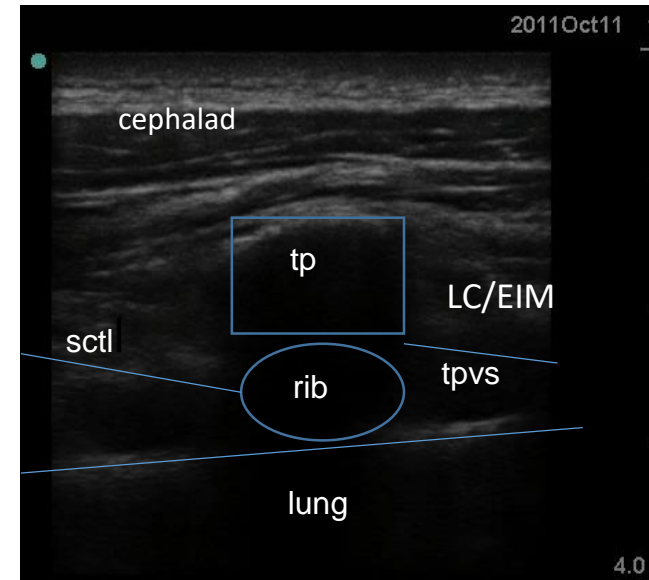
1. Good lung visualization.
2. Poor lung visualization.
3. Good lung visualization.

- The US probe should be tilted laterally to optimize the angle of incidence with the pleura.
- Otherwise, the pleural line on the US image will disappear (secondary to unfavorable angle of incidence).
- Different patients have different angle of the pleura and require different degrees of tilt to visualize the pleura.

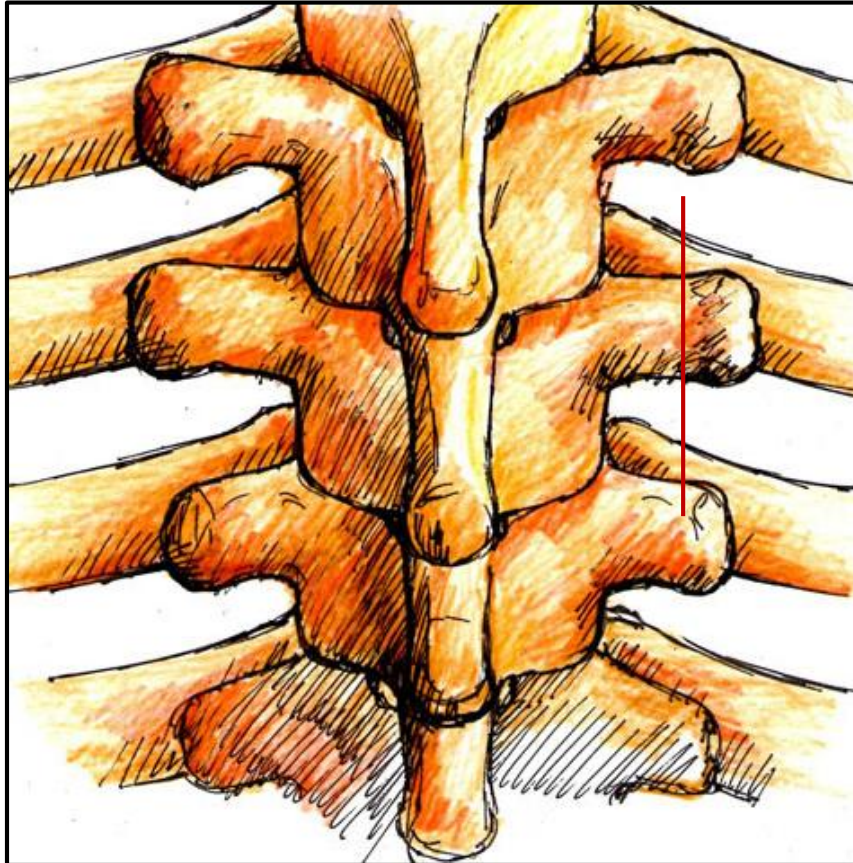
Sagittal scan over TP tip in the upper thorax with details (understanding what is obscured by the acoustic shadow)



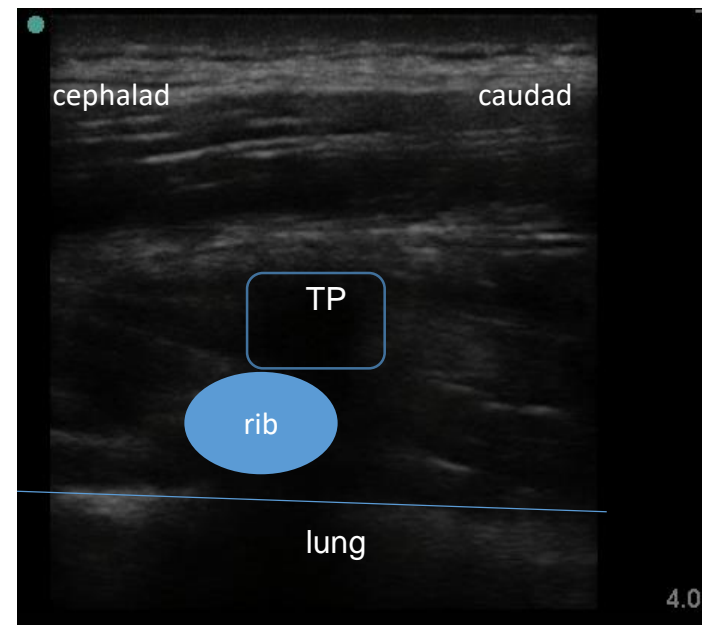
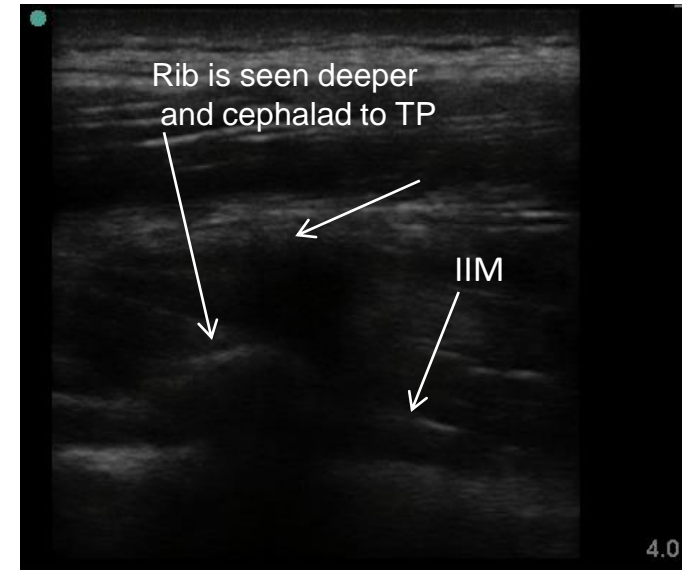
SCTL-superior costotransverse ligament
LC/EIM- levators costarum and external intercostal muscles
TPVS-thoracic paravertebral space
More medially, the multifidus and rotatores spinae are positioned posterior to SCTL
Due to the oblique course of the SCTL (from craniodorsal to caudoventral), probe adjustment may be needed to see it better



Same scan as before, but in low thoracic area where ribs are not completely overlapped by TPs

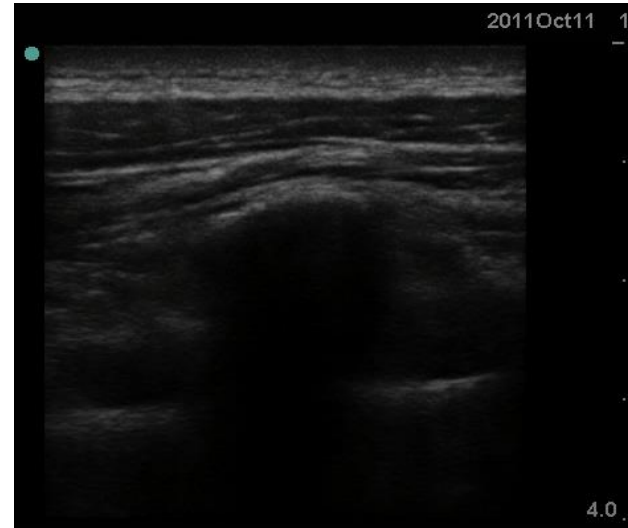
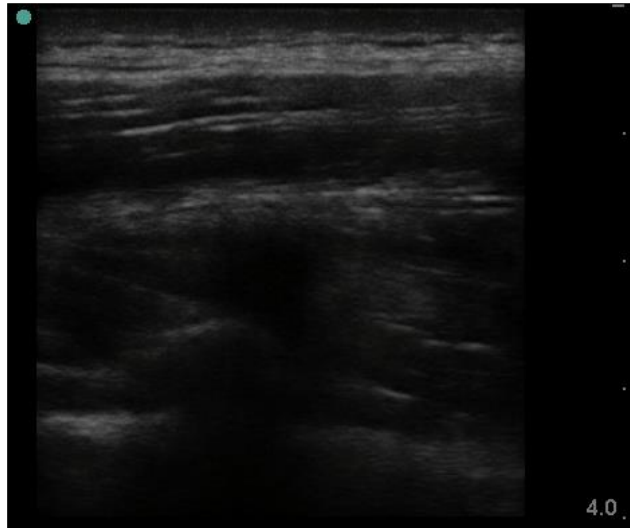


At this level, the ribs are not completely overlapped by TPs and one can see a part of the rib deeper and cephalad to TP


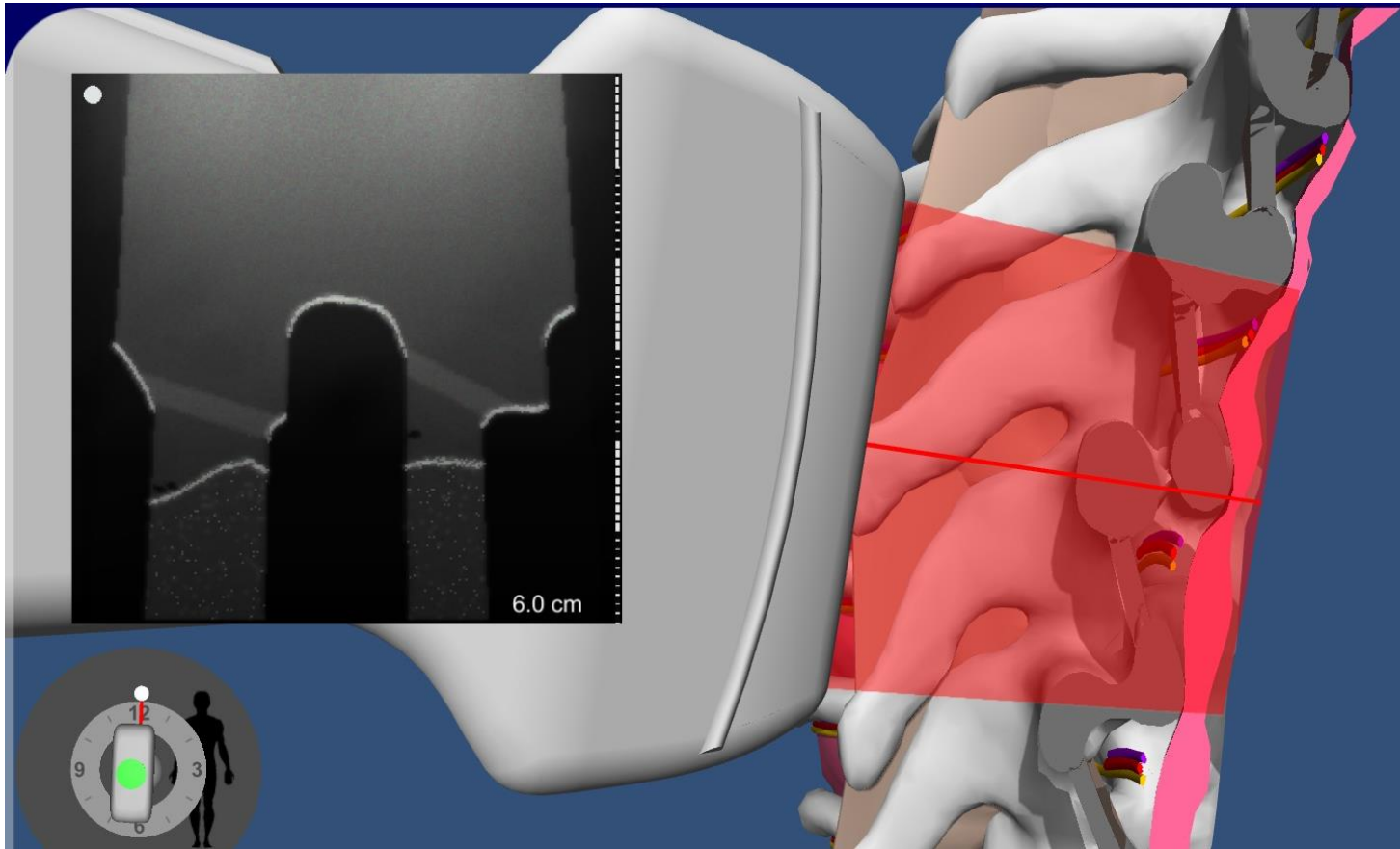


Review questions

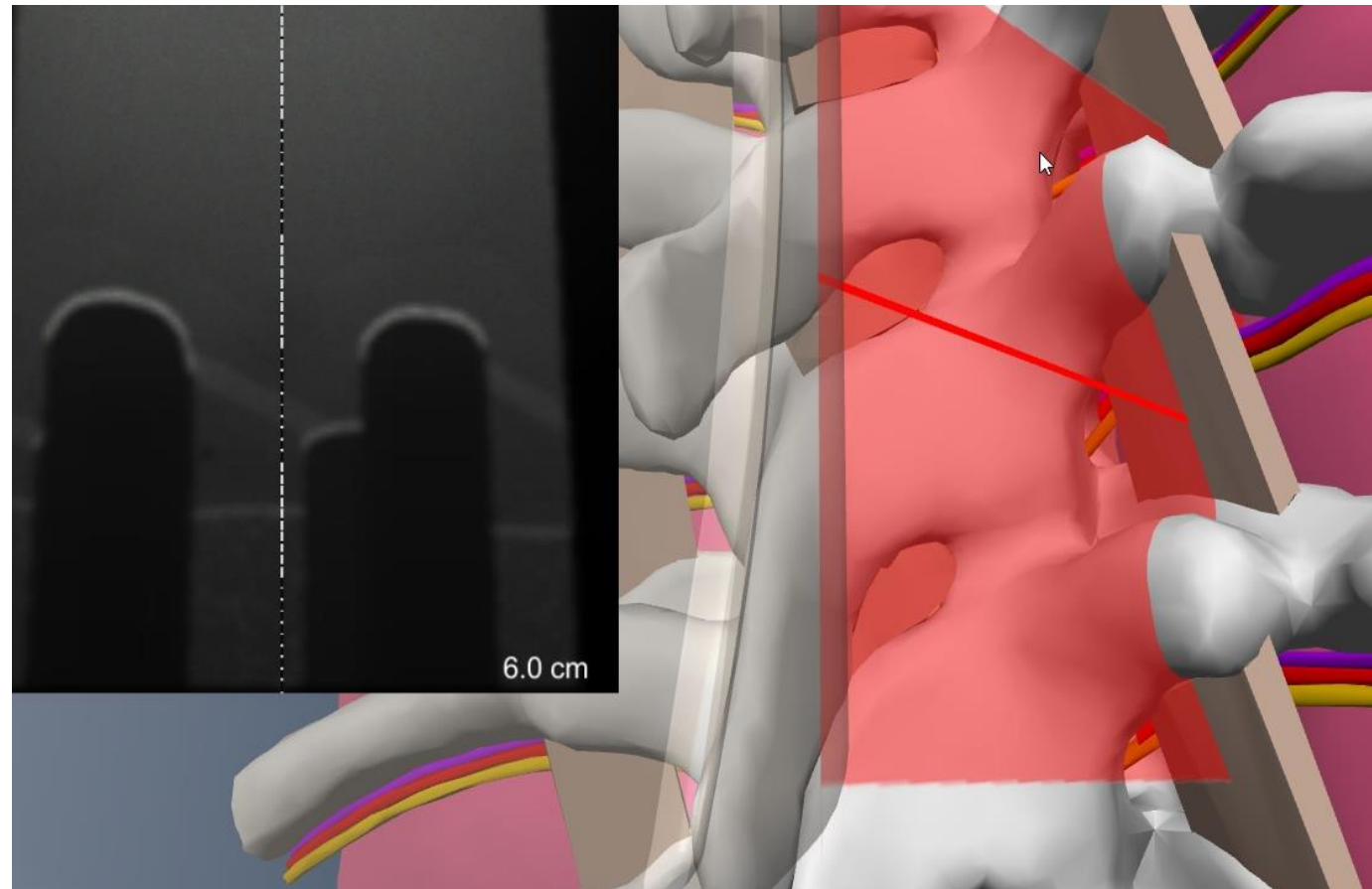
- Imagine the sagittal view of the ribs about 5 cm from midline and how this is different from sagittal view of the TPs about 3 cm from midline
- Explain why one may need a lateral tilt of the probe to see the lung better when we scan sagittal about 2.5-3 cm from midline
- Where is the cranial part of the image and where are the ribs on the images below

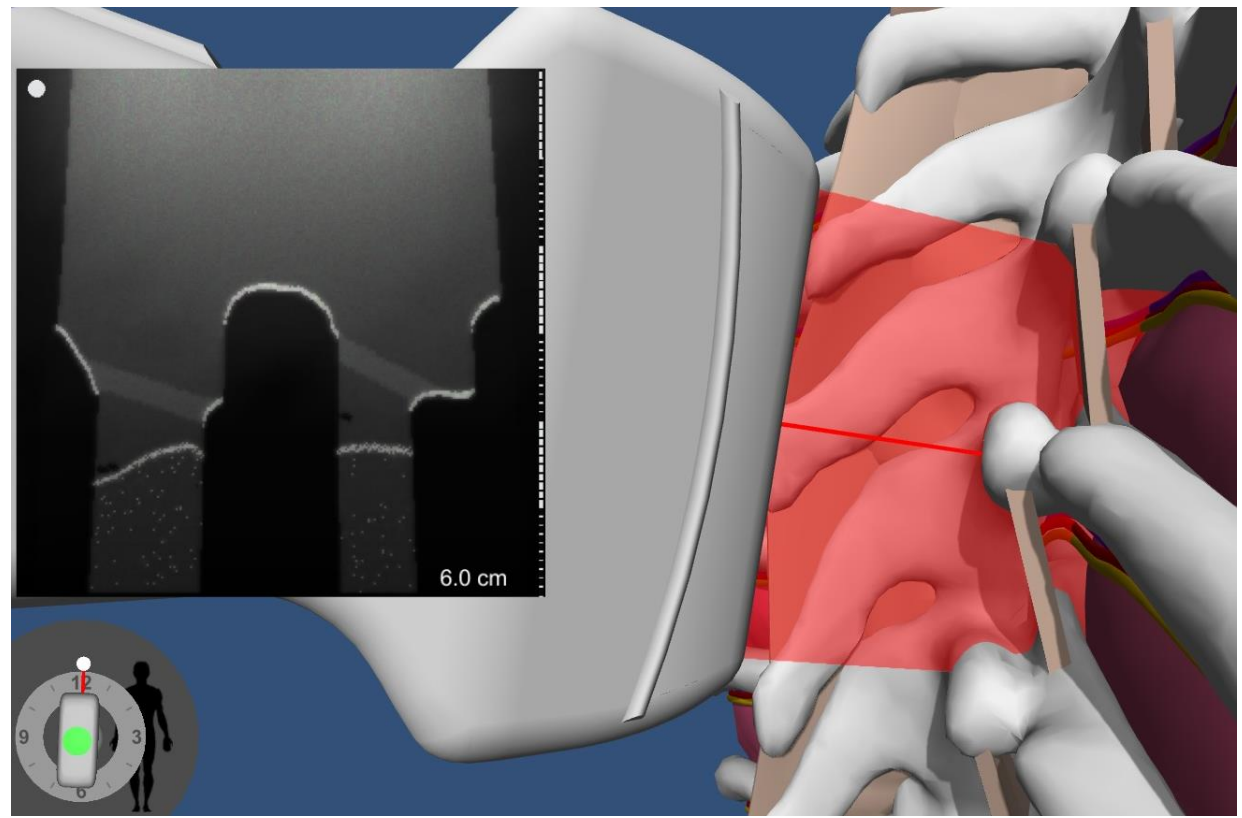
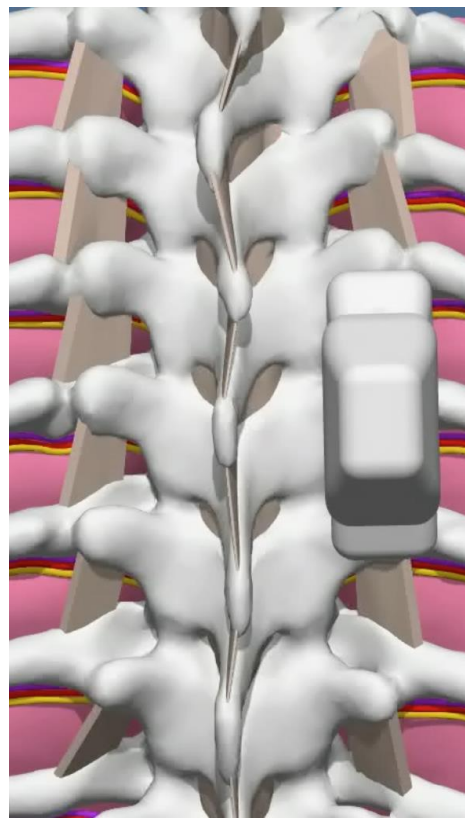



- Illustrating the same idea on the simulator with hybrid cross-section visualization mode
- **Acoustic shadow shows an obscured true outline of the TP and rib.** Novices frequently miss that point and expect to hit the bone, where in reality there is an unprotected lung in the shadow of the bone. It is also important that the shadow that is perceived as a bone will obscure the needle tip and give the false sense of security when one performs an US guided block here.



Sagittal Scan over the tip of TP on the simulator (ribs not completely overlapped by TP)





Sagittal **standard** TP image for the procedure:

Correct probe orientation:

The probe is not rotated, tilted or rocked

The US plane cuts through the tip of the TP and not root of the TP

The TP is in the middle of the screen

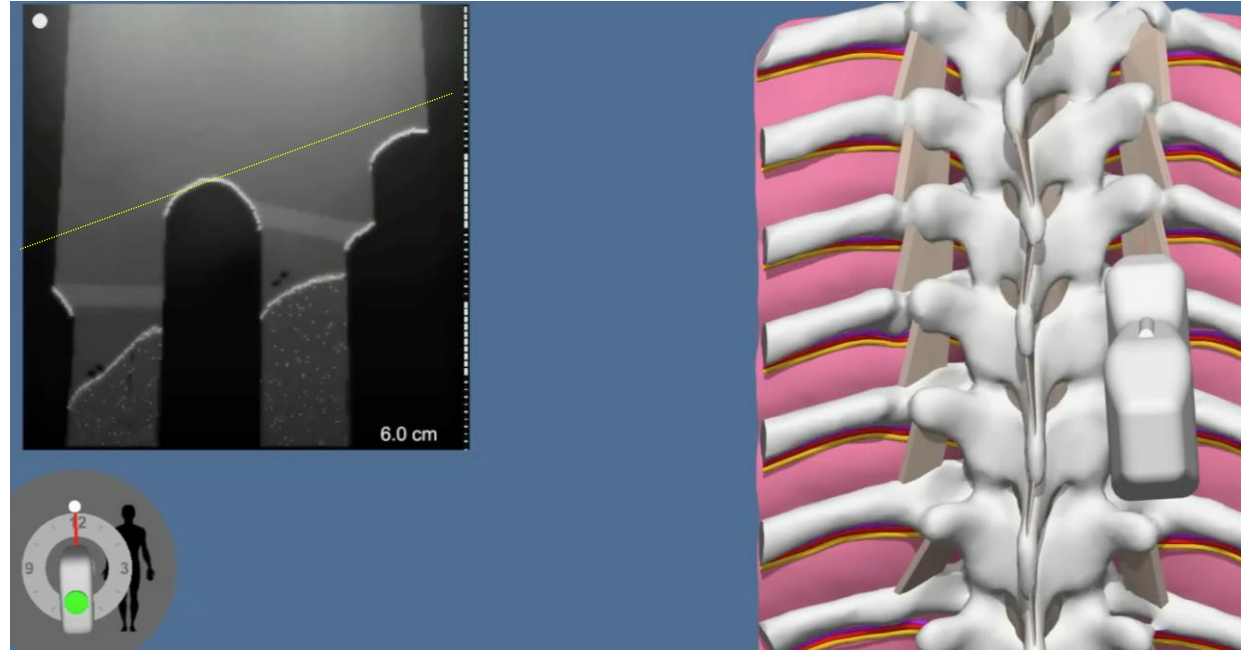
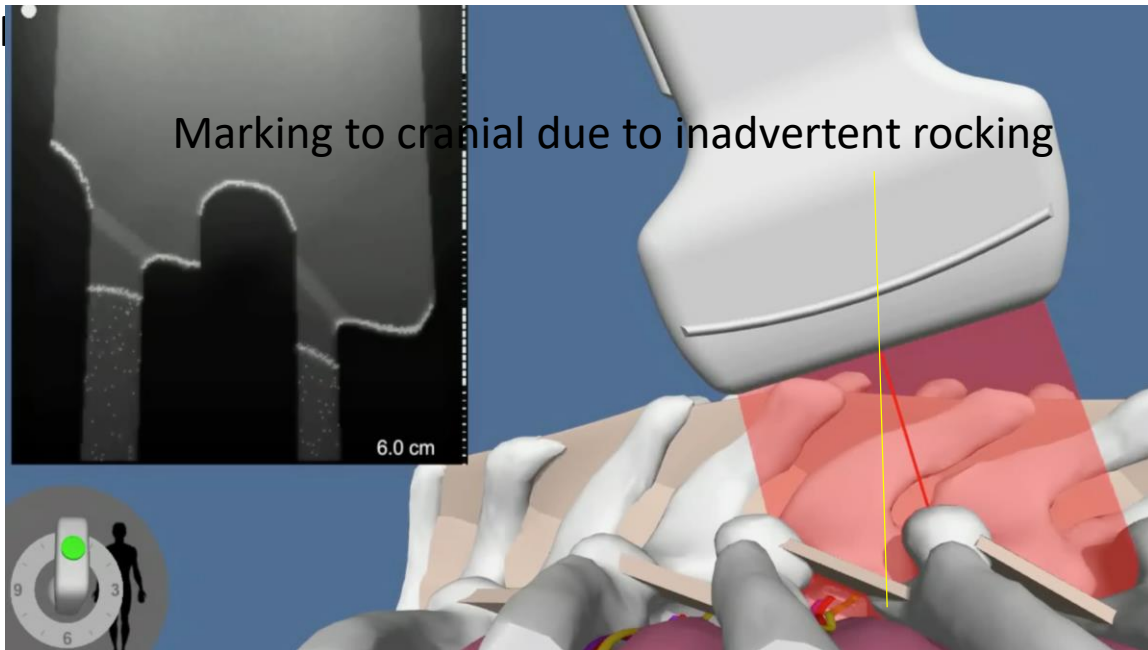
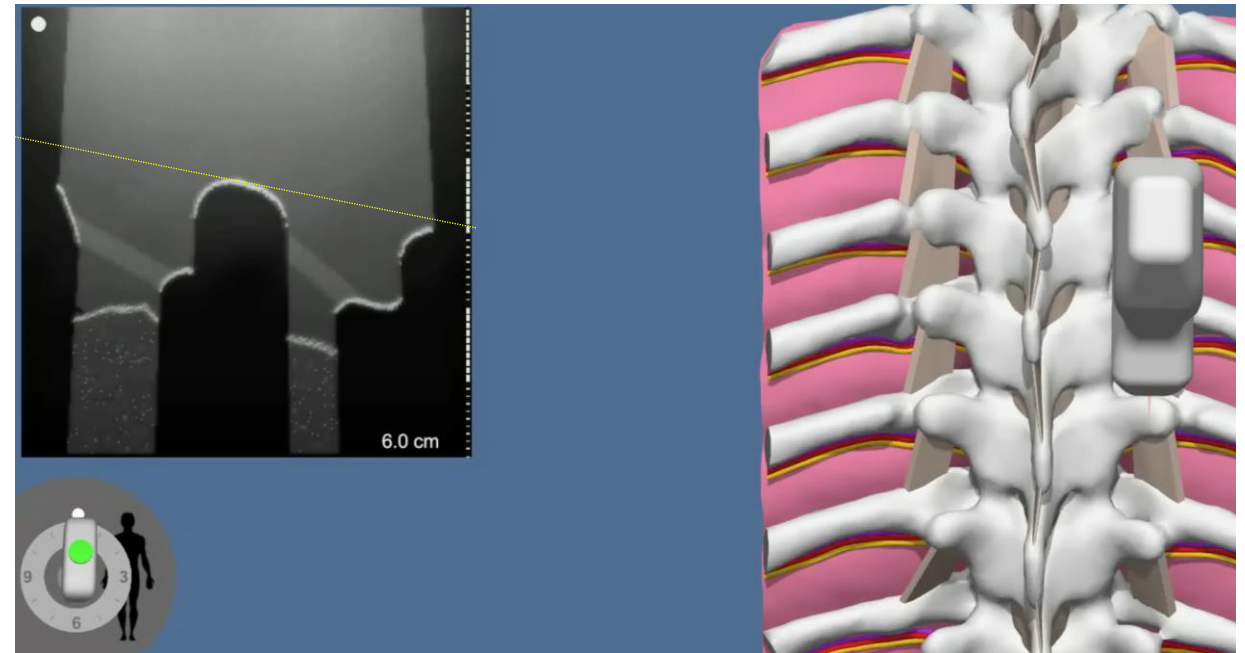
This image is used to mark projection of TP on the skin

It is also useful to eye ball the bone free window between the TP, the rib below and the depth from the TP to lung if the lung is well visualized. It is not the case if the lung is acutely turning ventrally and not well seen.

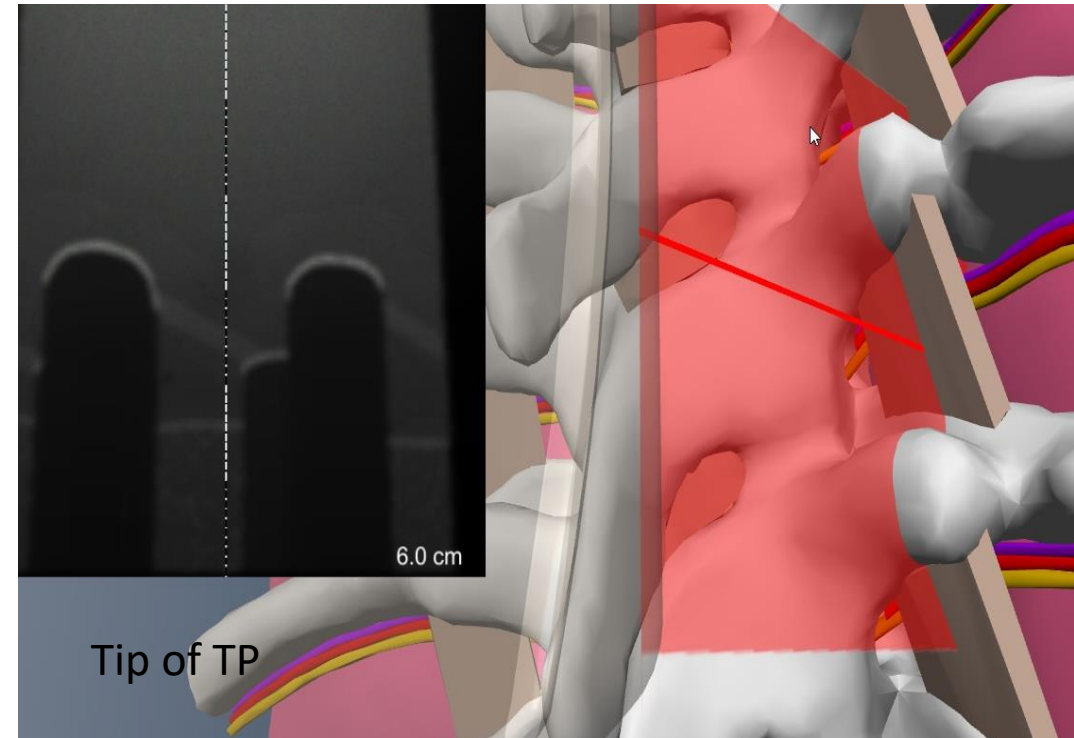
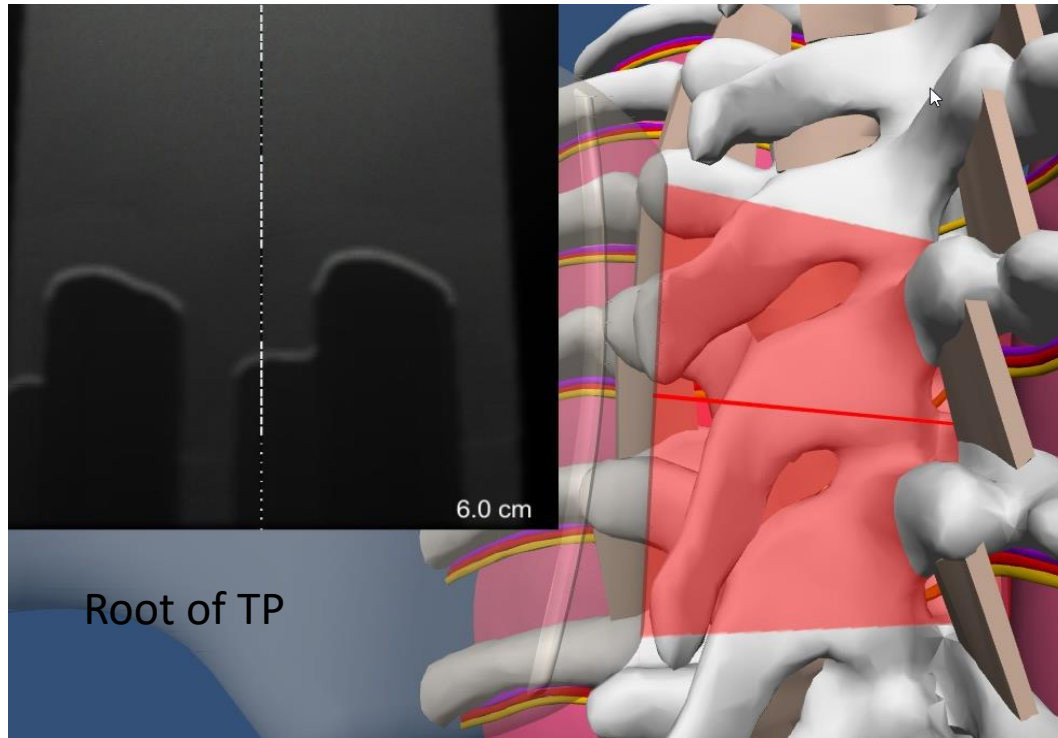
Rocking the probe when it is sagittal

As in the case with probe rocking when it is axial it will mostly affect marking. *If more pressure is applied on the p cranial side of the probe, marking will be erroneously too cranial. If more pressure is applied on the caudad side of the probe the skin mark would be too caudad from true skin projection.*

One may notice the inadvertent rocking by appreciating that structures that are normally horizontal are not horizontal on the image (see image on the right).



Tip of TP vs root of TP on US image



When the scan is done at the root of the TPs: TPs are deeper and wider, with the cephalad edge of the TP being more superficial than the caudad edge. The distance between adjacent TPs, or the TP above and the rib below, is smaller. The lung is almost never seen due to an unfavorable angle of incidence.

When the scan is done at the most ventral tip of TP (about 5mm medially from the lateral edge of the TP): the image is different in all mentioned aspects. Note: if we keep sliding the probe more lateral (past the tip of TP) the depth of the TP will start increasing again and the width of the TP in the sagittal scan will decrease.

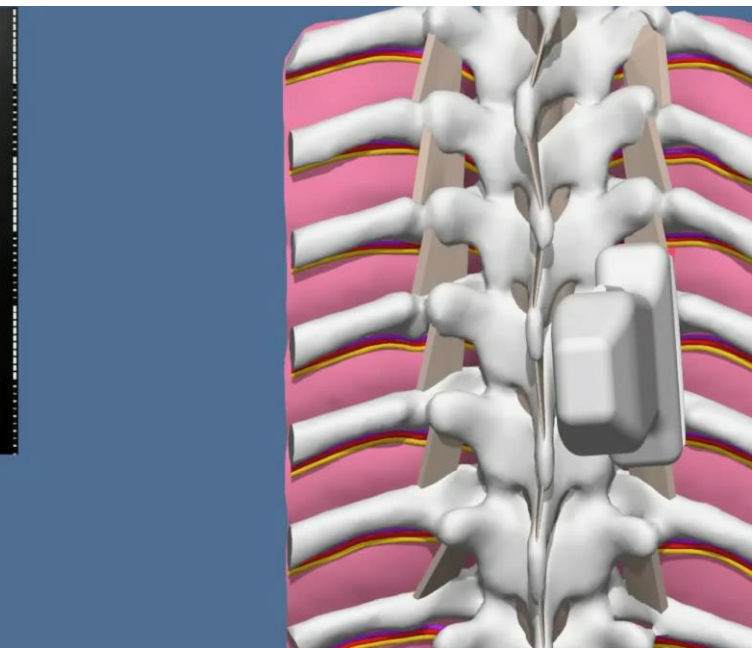

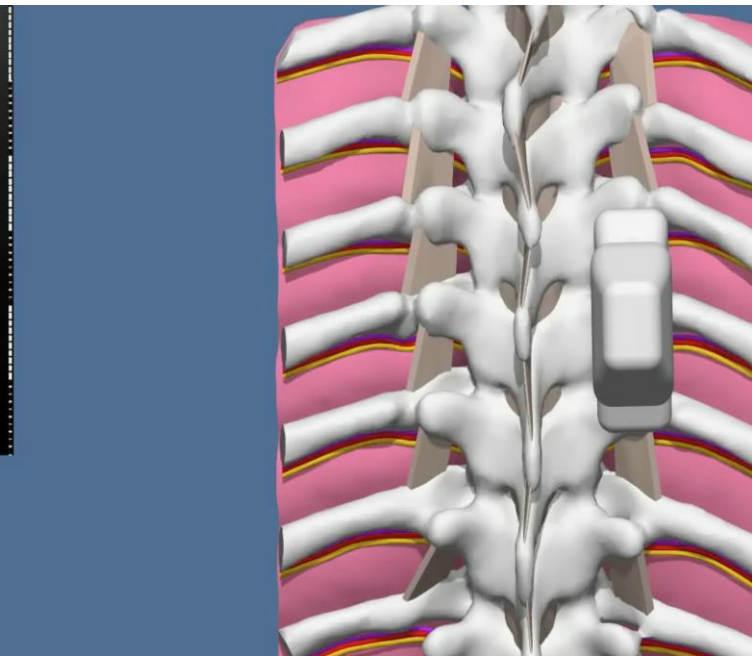

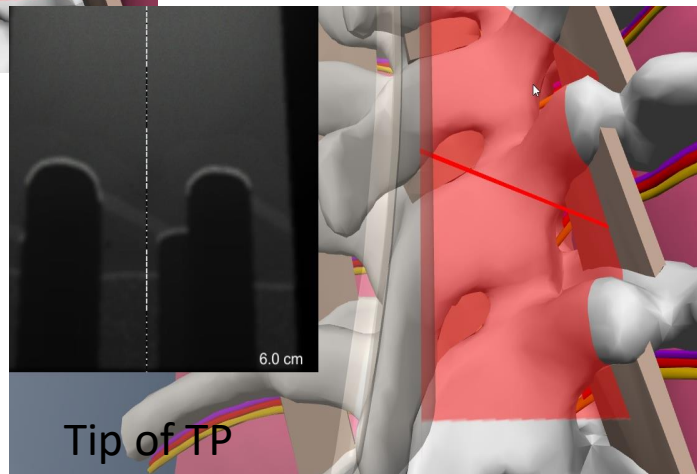
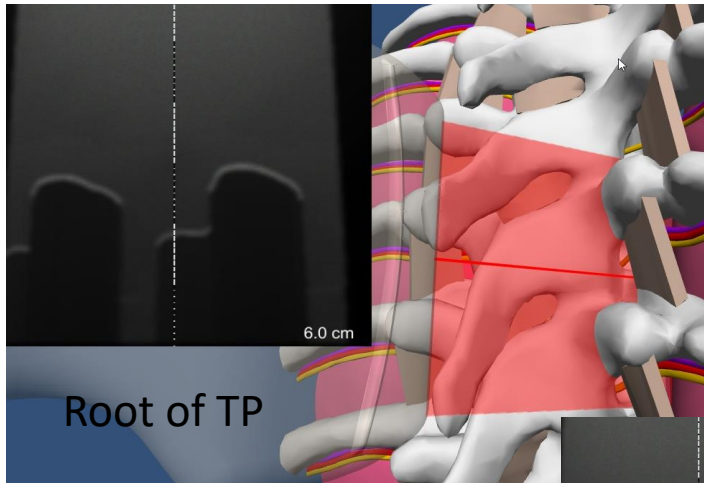
It is easier to recognize the tip of TP in the axial view. Draw a line over the skin and then place the probe in the sagittal orientation over that line

Another way to differentiate the tip of the TP from the root of TP on US (quick probe tilt)

Mild lateral tilting of the probe will result in a change of the image

If the original image was of the tip of the TP, the resulting image will be of the ribs (right top and bottom images)

If the original image was of the root of the TP, the resulting image will be the tip of TP

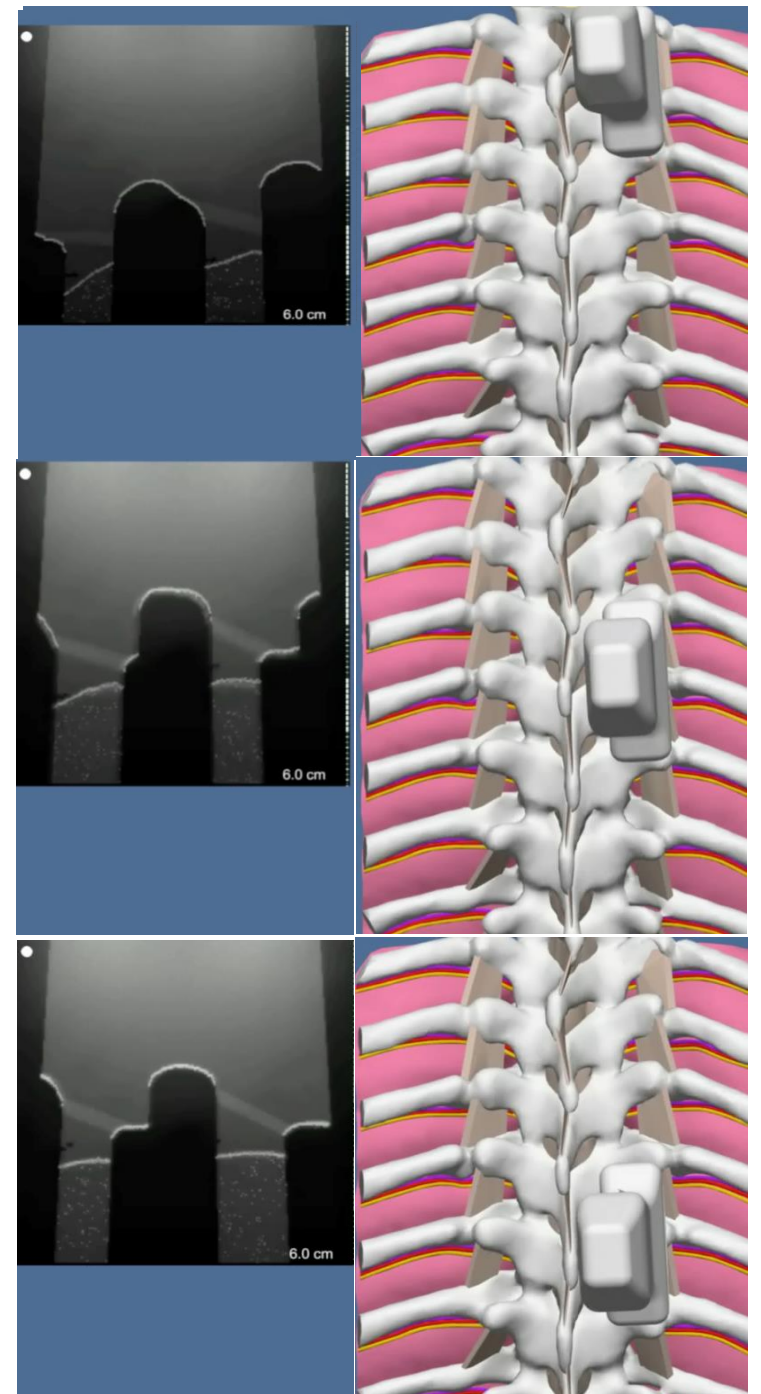


Difference in appearance of TP, rib and TPVS in paramedian sagittal view 2.5-3 cm from midline at different levels: upper thorax vs mid thorax vs low thorax



In upper thorax (top right): the ribs are completely overlapped by TP so we do not see them. The more cephalad you scan, the deeper the TPs are. The TPs are wider (from the cephalad to caudad edge), and the space between them less.

In mid thorax, we start seeing ribs that are located ventral to TPs. The ribs stick out cephalad. The TPs are more superficial than before and less wide (from the cephalad to caudad edge). Even though the distance between the TPs may be wider here than in upper thorax, the bone free window may be less due to the ribs taking up some of the space between TPs

In low thorax, the ribs stick out even more cephalad than before. The TPs are narrower (from cephalad to caudad edge) than before and are deeper (from the skin) again



Marking tip of TP in sagittal plane




The outline of TP shape in sagittal view may present some challenge for marking (what to mark?) Most of the time surface of TP is relatively flat and depth from skin to TP is relatively the same in its most cranial, most caudad, and in the middle parts (left image)

Occasionally (mostly in upper thorax- see right image) there is a more rounded cross section with up to 5 mm difference between most superficial part and the deepest part (see yellow line vs white dashed line on the right image) It is wise to mark most prominent (superficial part of TP (yellow).

Most of the time, the mid portion of the TP in sagittal view will be a good target for a marking (if TP is flat and wide, then favor the caudad portion)

Review questions

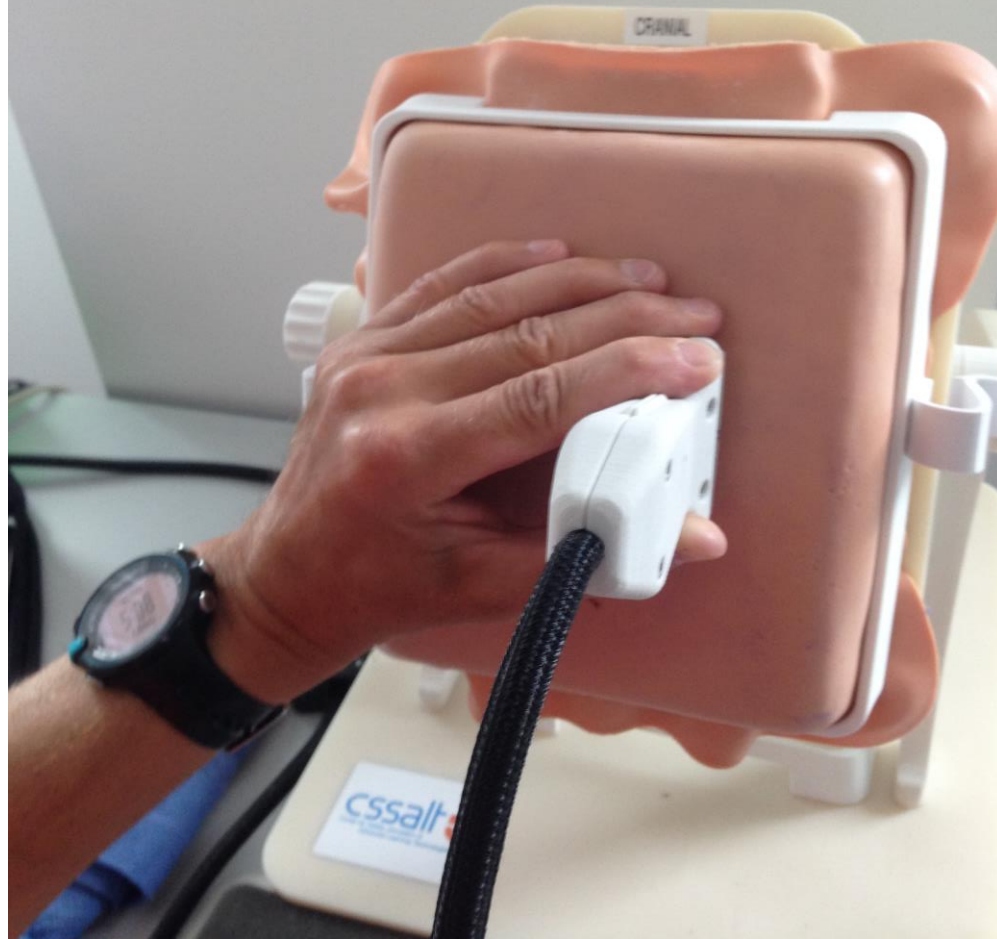- Explain the difference between outlines of anatomical cross section and US image
- Explain the difference in sagittal US image of TP root vs TP tip, what trick could be used to help to differentiate those
- Explain how one can suspect rocking of the probe based on the image and how rocking affects marking
- What part of the TP should you put in the middle of the screen for marking?
- Name which part of thorax those images below belong to



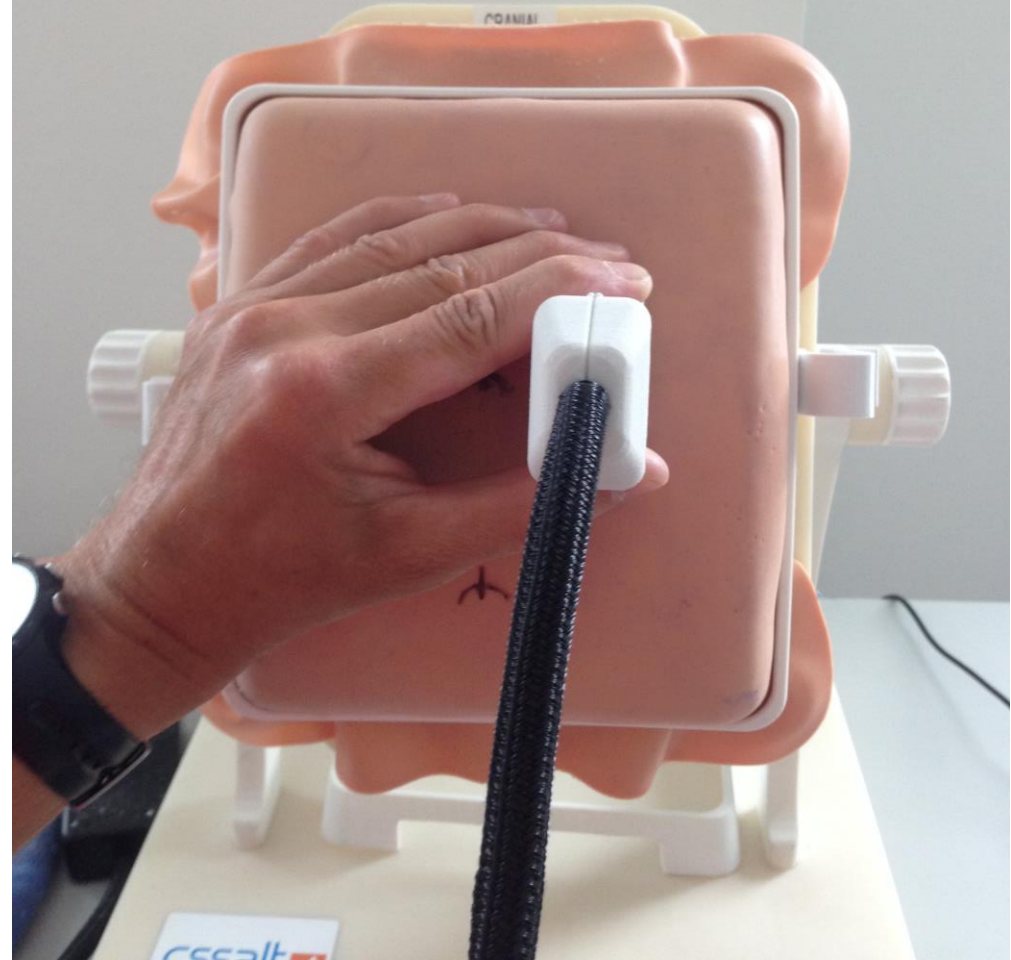Choosing the correct point of view during image acquisition

- Incorrect point of view:
 - Too much off to the left or right to the target
 - Too much cranial or caudad to the target
 - Both of these views will affect your ability to see if your probe is perpendicular to all planes (parallax error). This may also inadvertently increase the chance of rocking or tilting the probe
- When the patient is sitting and we are facing his or her back, most practitioners are good at positioning themselves in the middle but still commonly make errors on choosing the eye level (too cranial or too caudad)
- When the patient is lateral or prone we more commonly error in both axial and sagittal planes

Different point of view of the same US probe position




Correct point of view



Incorrect point of view may lead to inadvertent tilting, rocking, and rotating of the probe. Incorrect point of view on the left because you are looking off to the side and above the correct eye level. Better view on the right (one can not see any side of the probe more than others).

Our trick on finding a correct point of view relative to the patient (patient sitting)

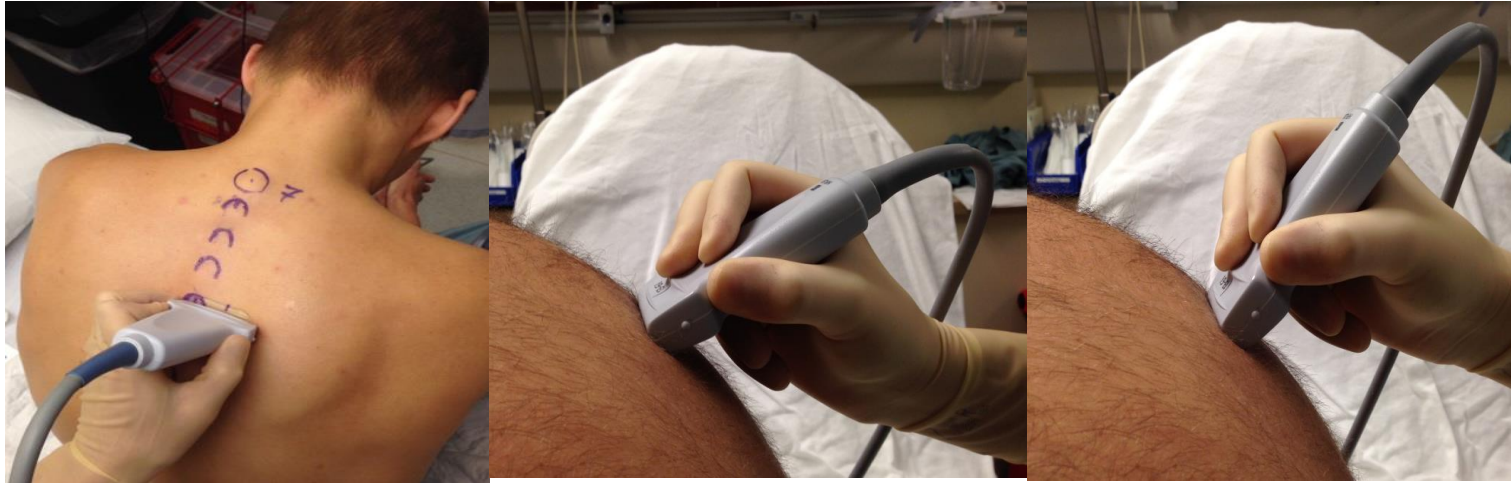- When you determined a required level for a block, take a moment to assume a correct point of view by using the following recommendation:
- When your face is about arm reach from the patient's back, position the US probe sagittal at the level of the block and make sure that you do not rock the probe. Now, adjust your eye level by moving the patient, or yourself up and down without tilting your head, so you have an equal view of the cranial and caudad sides of the probe.
- For verification of the correct point of view in orthogonal plane, rotate the probe 90 degrees and repeat adjustment if needed (equal view of lateral and medial sides of the transducer)
- **Tip: when you are at the stage of the procedure when you have to see the needle depth marking, it is OK to change your point of view for a few seconds by using a step stool.**



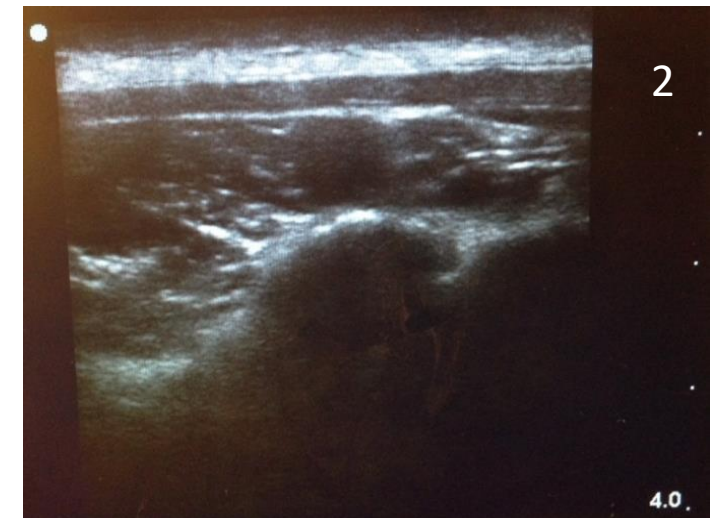
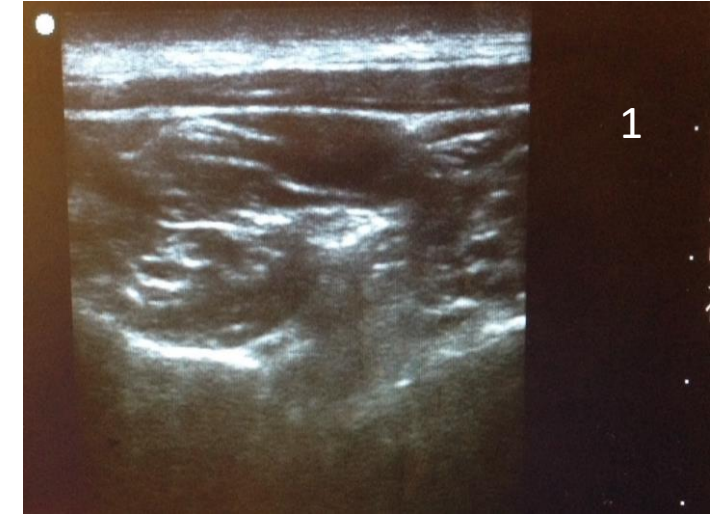
Acquiring US images in a stepwise approach (example)

- Choose the **appropriate transducer** (e.g. high frequency for skinnier patients). Use optimal US machine settings for best resolution (MSK or Nerves) and adjust **depth** (about 4cm for TPVB). Confirm position of **screen orientation marker (on the upper left)**
- **When positioning the transducer, pay attention to the probe orientation** (tactile marker up (cephalad) for a sagittal scan and to the left for axial scan). Apply an adequate amount of gel.
- **Position the transducer to the skin location to acquire the image of interest:** immediately lateral to midline for axial scan; 2.5-3 cm from midline for sagittal scan
- **Adjust the probe position** based on the image (move it up/down/lateral/medial). If needed **adjust machine settings depth/gain**.
- **Look back at the transducer** to make sure that it is not tilted or rocked and adjust accordingly. After initial coarse adjustments, **fine tune to obtain a nice “clean standard image”**.
- *Note: on the simulator you will not be able to adjust machine settings and you will not need gel. Using tapping motions on the edges of the transducer to determine probe orientation (before applying the probe to the surface of the phantom) does not work. The rest is conceptually the same*

Example of acquiring and fine-tuning the axial image over the costo-transverse junction

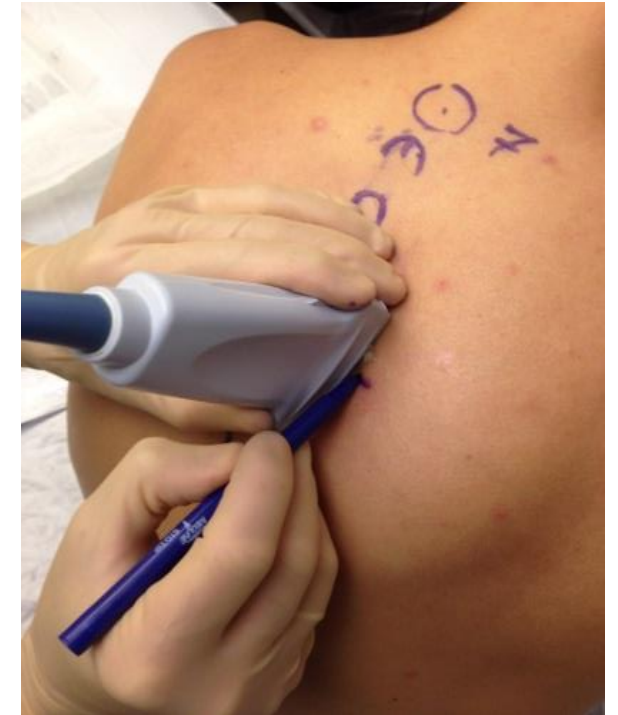
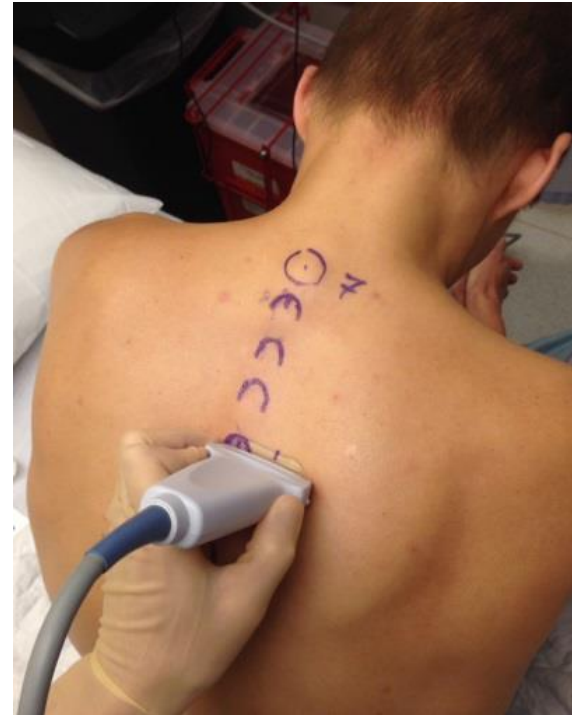
With the probe orientation marker to the left position, place the transducer immediately lateral to midline at the level of appropriate SP and assess the image. Adjust US settings as needed (gain, depth). In this example, we see pleura and IAP in our initial US image. To move the US plane over the costotransverse junction, we can either slide the probe caudad without changing the angle between transducer and surface or tilt the probe caudad. If our probe was slightly tilted cephalad to begin with, we just have to untilt it to acquire our image. In this example, the tip of TP is perfectly centered in our image so we do not need to move transducer to the left or right. In summary, after obtaining the initial image, we may need to make adjustments to optimize our image (change machine settings, manipulate the probe (slide cephalad/caudad, slide left/right, tilt/untilt/rotate/rock probe)).



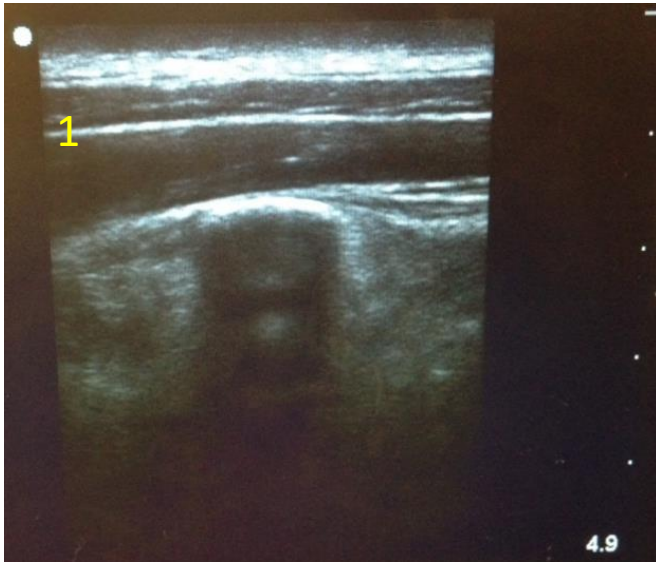
Holding the probe during image acquisition and skin marking

- Hold the probe close to the scanning surface (not close to the cable)
- The hand should be braced on the patient for stability but able to make mild adjustments (press harder, tilt, rotate, slide or rock if needed)
- Pay attention to the way you hold a probe to avoid inadvertent tilting or rocking when you do not intend those maneuvers
- Use of the second hand while optimizing the image is helpful occasionally
- Eye alignment with the probe is important to avoid the parallax error that will result in inaccurate skin markings

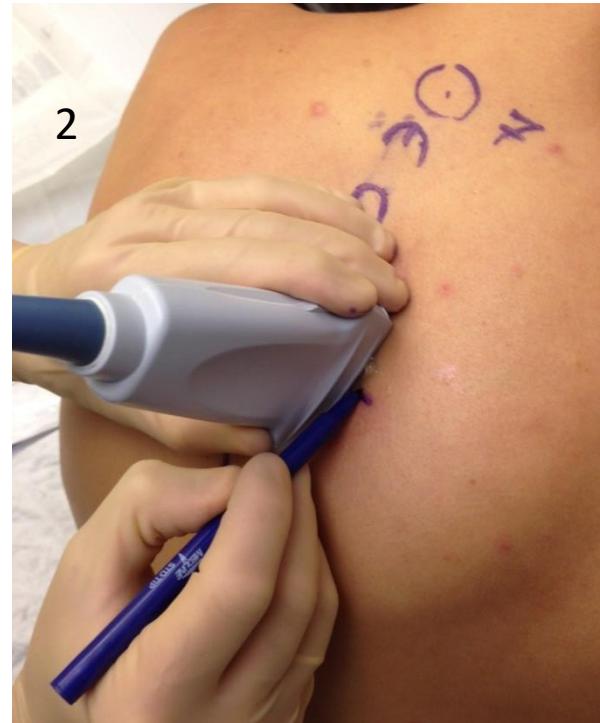


Hold the probe close to the scanning surface and the scanning hand on the patient for stability

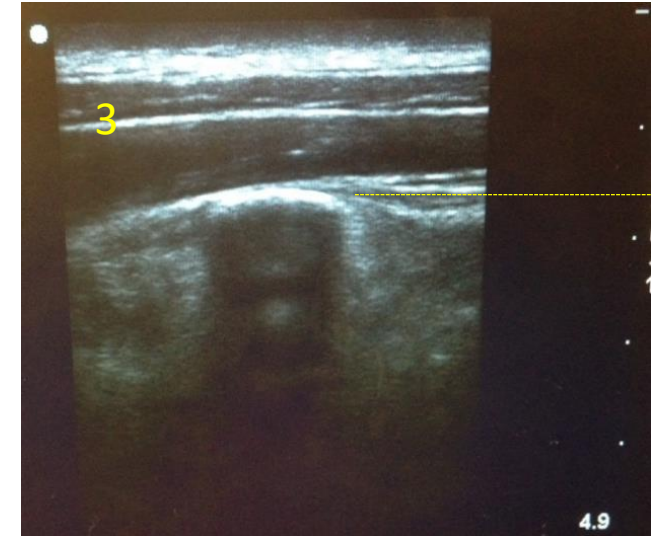
Marking and measuring with US (basic principles)



Position the structure of interest in the center of the screen. Here, our structure of interest is the TP in the sagittal plane.

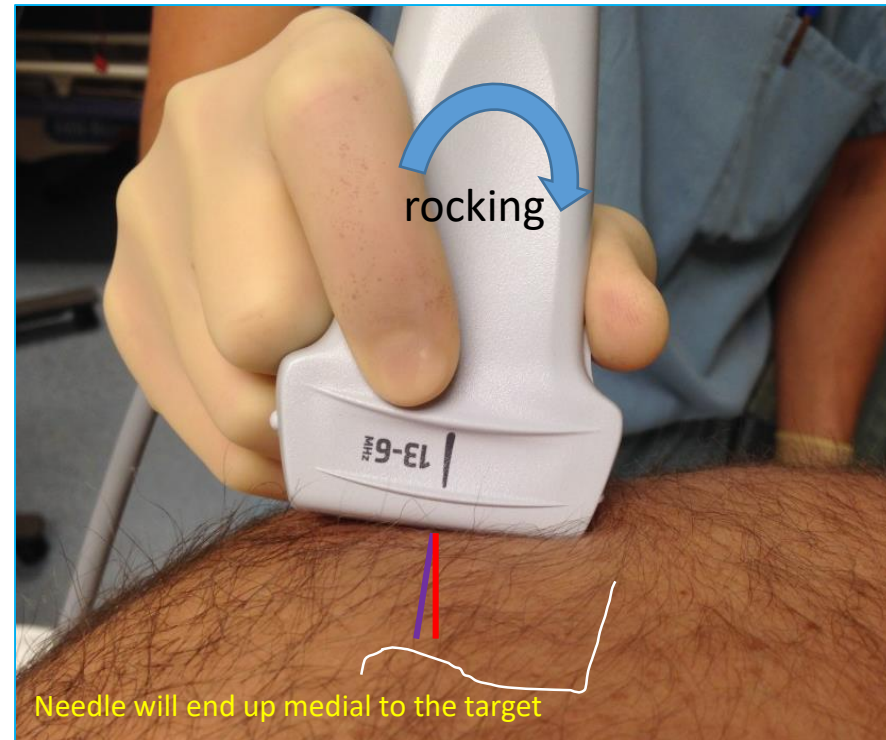
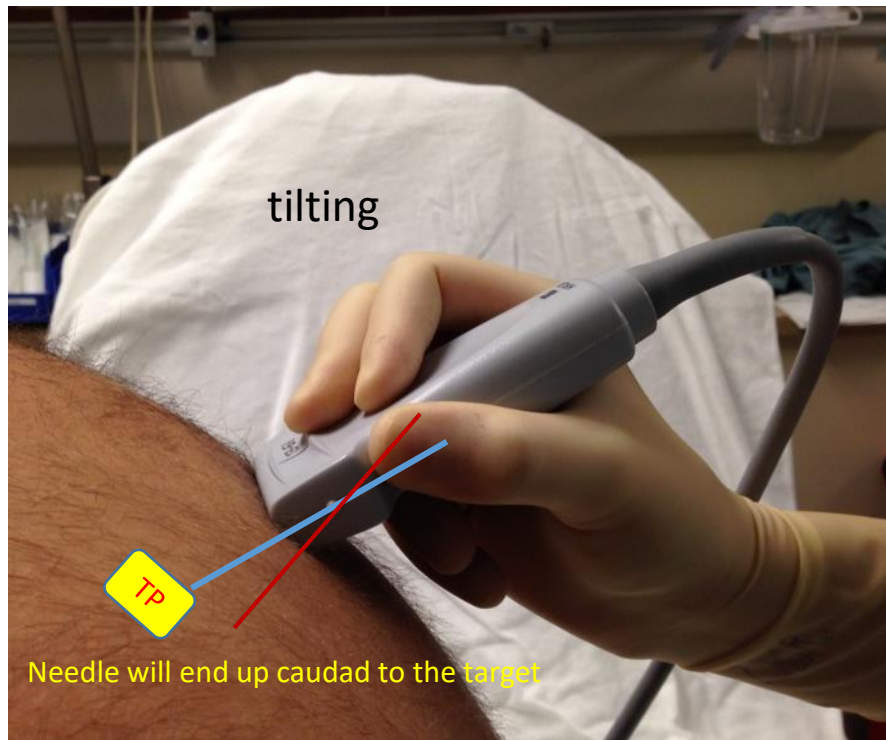


Mark the middle (along the length, not width) of the probe to outline the skin projection of the TP in sagittal plane.



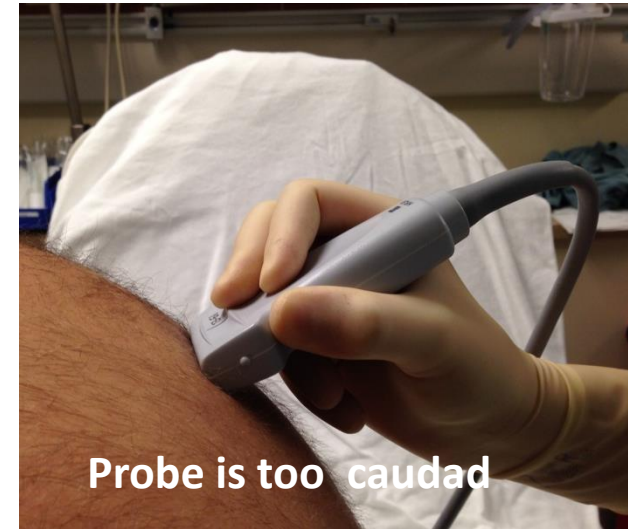
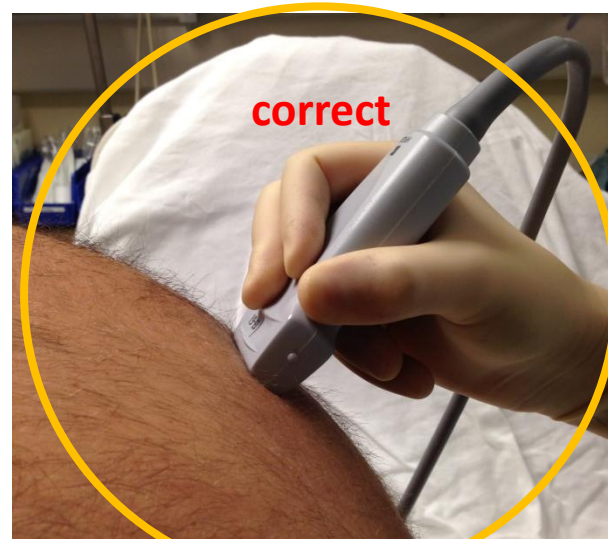
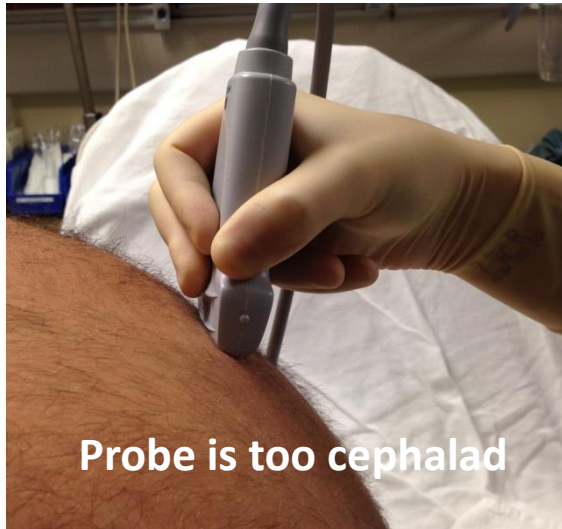
Without excess pressure on the probe, note the depth of TP by looking at the depth marks on the right side of the screen (in this case, slightly greater than 1.5 cm). One can also freeze the image and use the US caliper tool for more accurate measurements.

Pitfalls of marking and measuring with US (probe tilting/rocking as a source of errors)

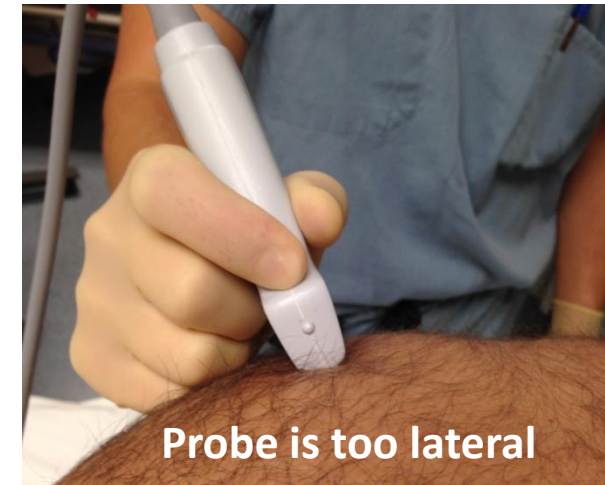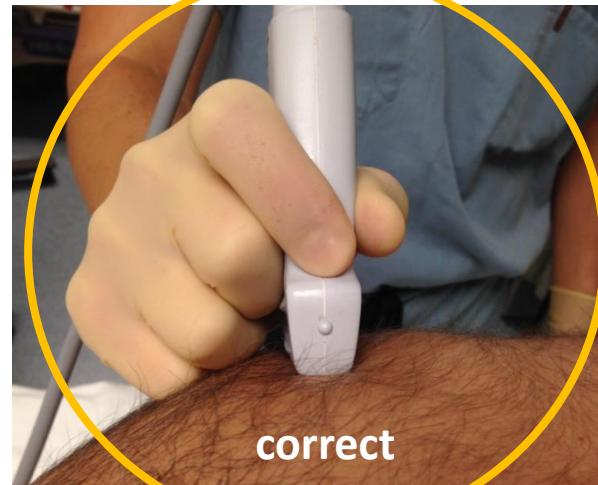

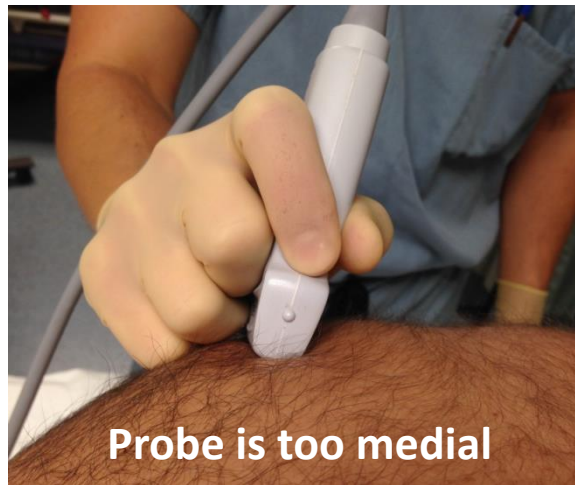
If the ultrasound probe is not perpendicular to all planes, if it is tilted or rocked, the skin marking and depth measurements will be inaccurate when needle is advanced perpendicular to all planes. Marking is accurate only when both the US probe and needle are perpendicular to the surface in all planes or when the needle angulation is the same as the US plane angulation.

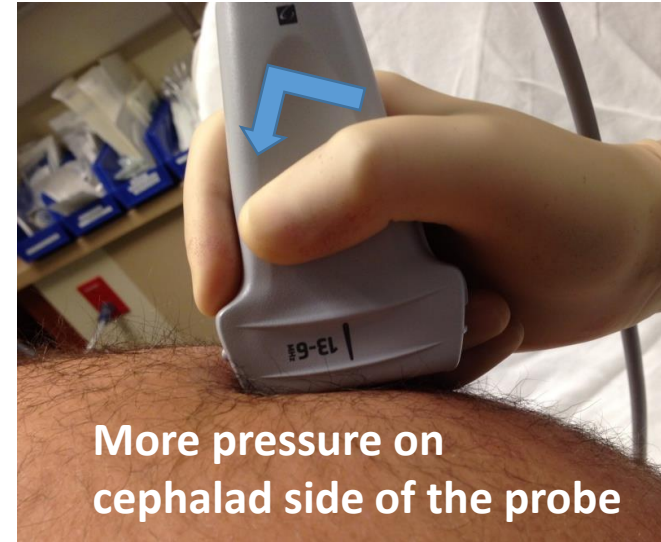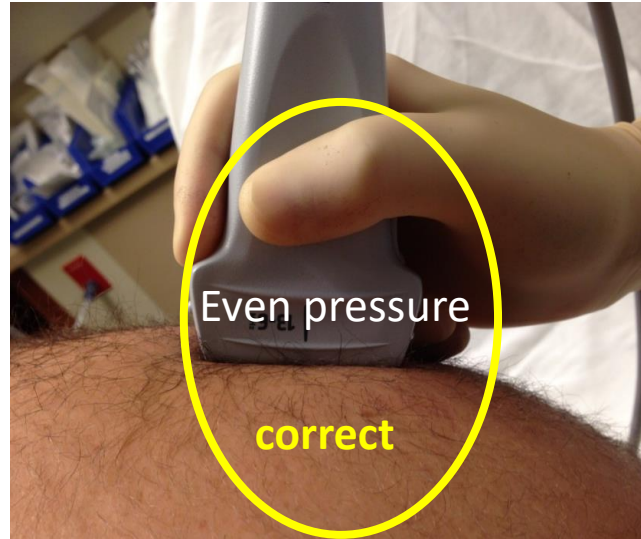
US probe TILTING



Avoid tilting the probe in axial plane (above) or sagittal plane (below) when marking deep landmarks

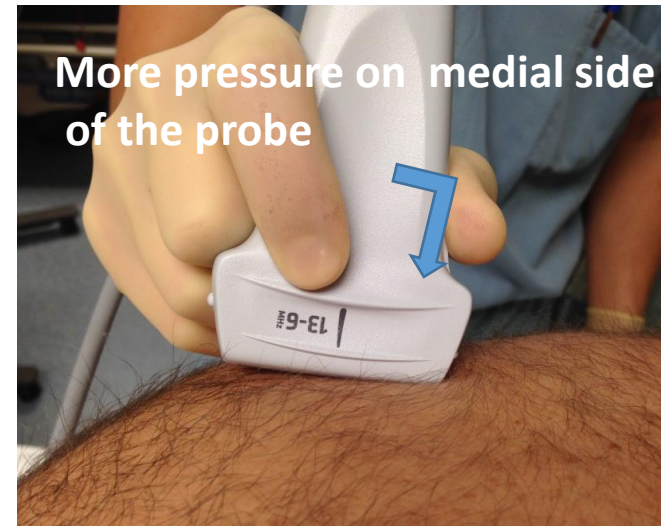
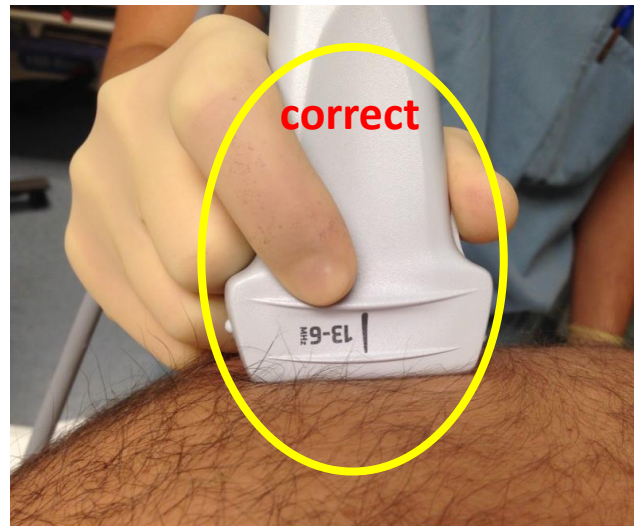


US probe rocking (more pressure on one side of the probe)



Mark will be more cephalad than true projection

Avoid rocking the probe in sagittal plane (above) or axial plane (below)

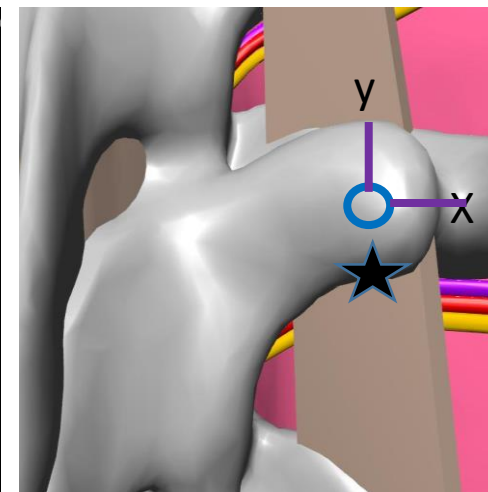
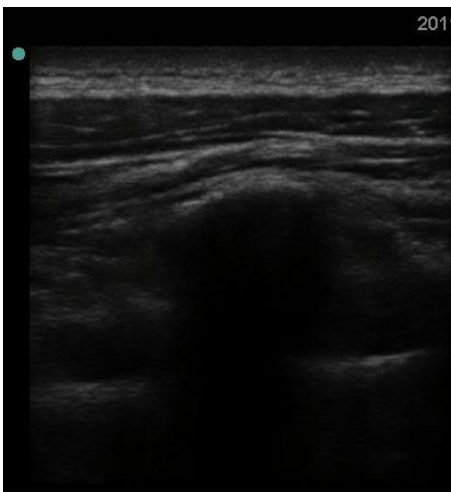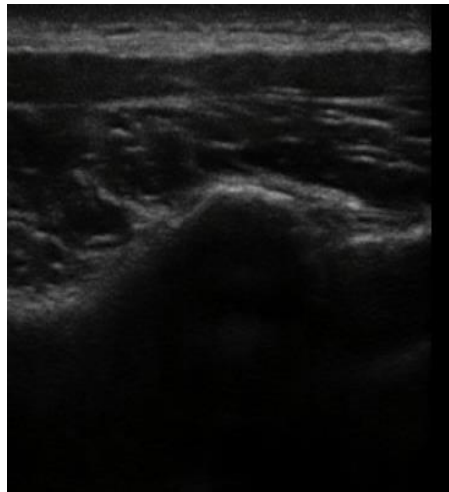
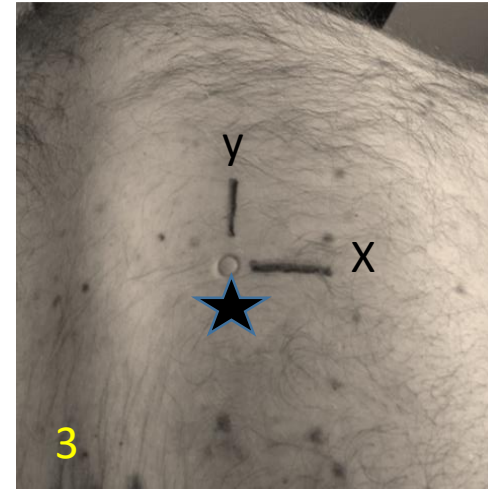
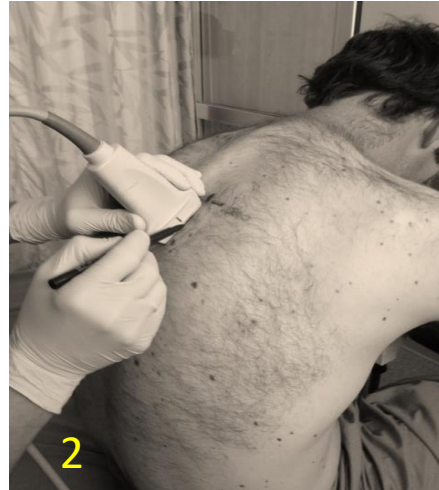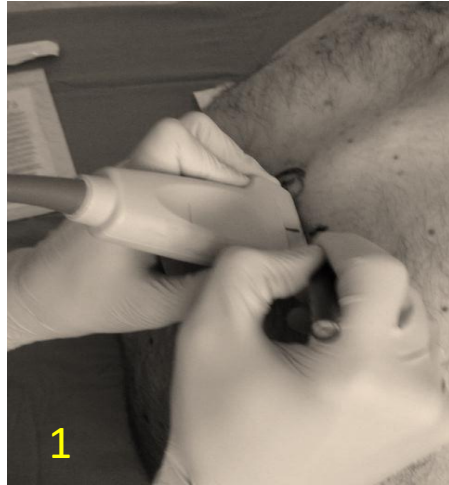


Mark will be more medial than true projection

Review questions

- Explain how suboptimal point of view may negatively affect US marking
- How can one find a correct point of view. Why point of view during needling could be different from one during US marking
- What are the basic rules of holding and manipulating the probe
- What are the pitfalls of inadvertent tilting and rocking the probe
- Name the typical steps of the image acquisition
- Name the typical steps during US assisted marking of the skin
- Name the pitfalls during marking
- What are the pitfalls during depth measurements with US

US marking of the tip of TP in 3 steps. Needle entry 5 mm below it (star)

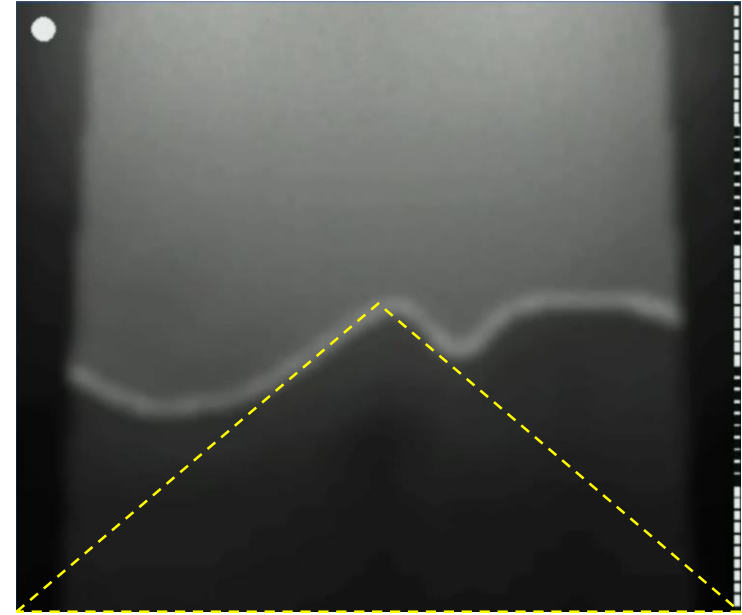
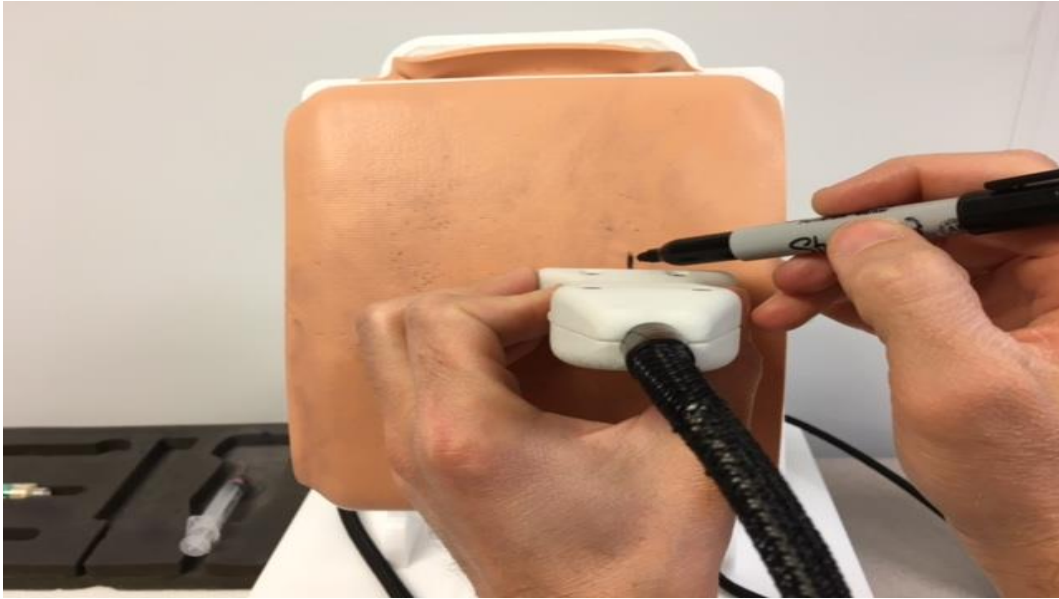

1. Probe in **axial plane**,
Tip of TP image in the
middle of the US screen.
Mark Y line at the
middle of the probe.

2. Probe in **sagittal plane**,
on the Y line, **tip of TP** is in
the middle of the screen.
Mark X line at the middle
of the probe.

3. Connect the X and Y
lines (TP tip projection)
Mark the needle entry 5
mm below the cross
mark

US marking of the tip of TP in 3 steps: marking on the simulator (step1)




Step 1: Mark the projection of TP tip in axial plane. Draw a vertical line through the mark (line should be longer than length of the US probe, this will help position it correct for a sagittal scan)

If there is no midline marking on the US screen (We use M mode). If there is no M mode capability, imagine a triangle with corners at the sides of the image and tip at the TP (dashed yellow line). Move the probe left and right until the imaginary triangle has sides of equal length.




US marking of the tip of TP in 3 steps: marking on the simulator (Step 2 and 3)



Step 2: Place transducer with sagittal orientation over the line that you drew during previous step. Slide it up or down until the middle of TP is centered on the screen. Use equal sided triangle trick (from the previous slide). Mark skin at the center of the probe. Make sure you move your head further to the side so that you have a better point of view of the middle of the transducer to avoid a parallax error during marking

Step3: extend the lines from Steps 1 & 2 and note the point where they intercept. Needle entry is 5 mm lower of the cross mark. (TP is about 1cm tall so 5 mm below its tip will be about at the caudad edge of TP)

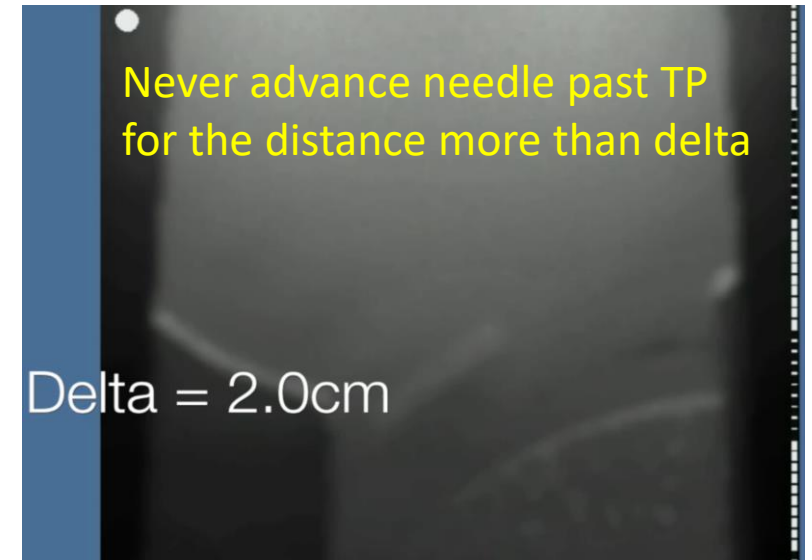
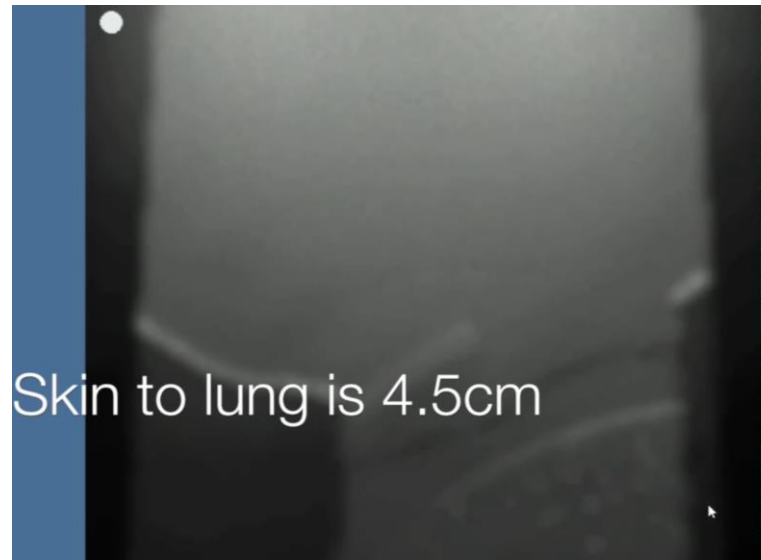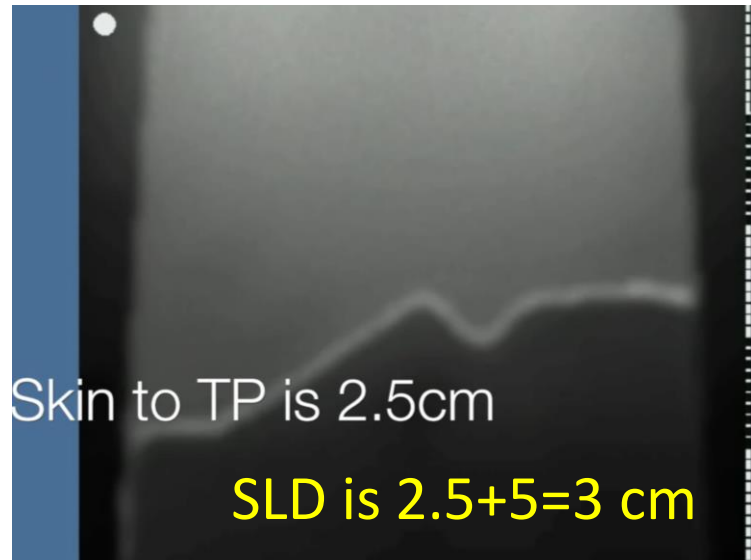




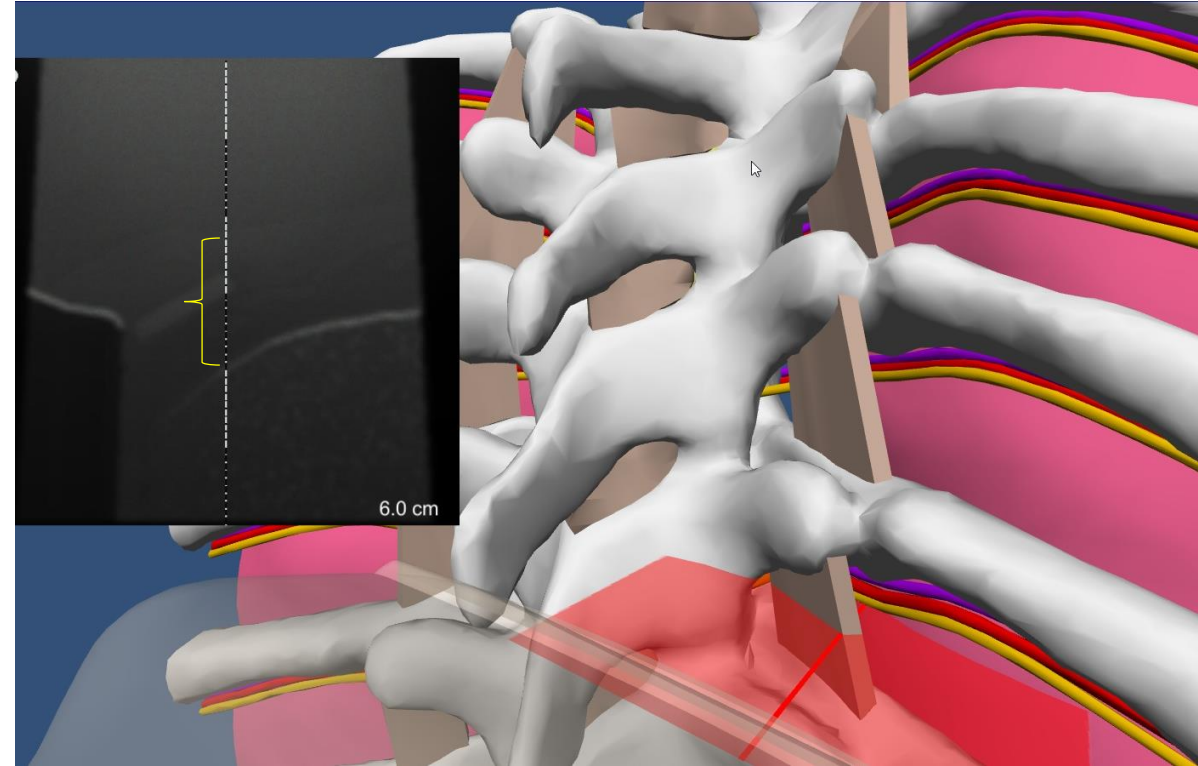
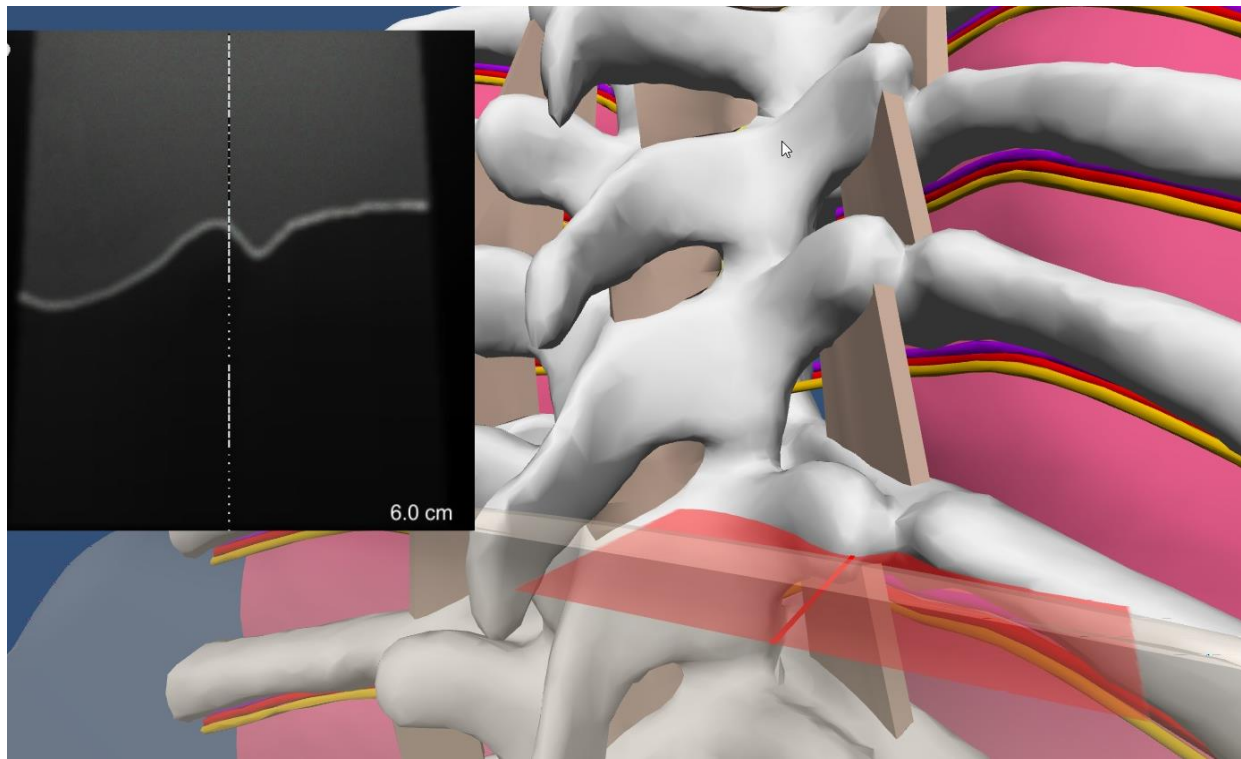
Measurements of distances (skin to TP, skin to lung, calculating delta)

Place the US probe so its middle is against the vertical mark and its upper edge is at the level of horizontal mark and look at the screen after tilting probe slightly up. You should see Modified standard axial view of TP with TP in the middle (if it is not in the middle-adjust and remark). Make sure you do not rock the probe medially and do not apply too much pressure. Note the depth from skin to TP. Add 5 mm to get SLD

Now “untilt” the probe so it is perpendicular to the skin. You should see standard axial TPVS view. Note the depth to the lung at the middle of the image. Now you can calculate delta. If Delta is more than 15 mm than IA is 10 mm and SA is 5 mm.

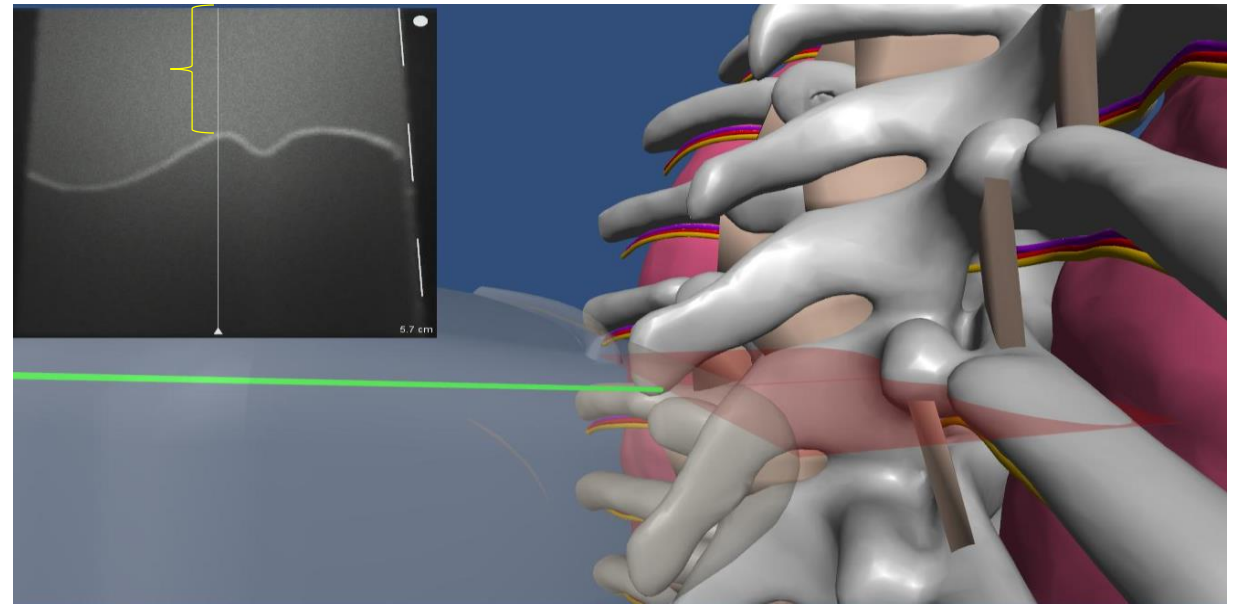
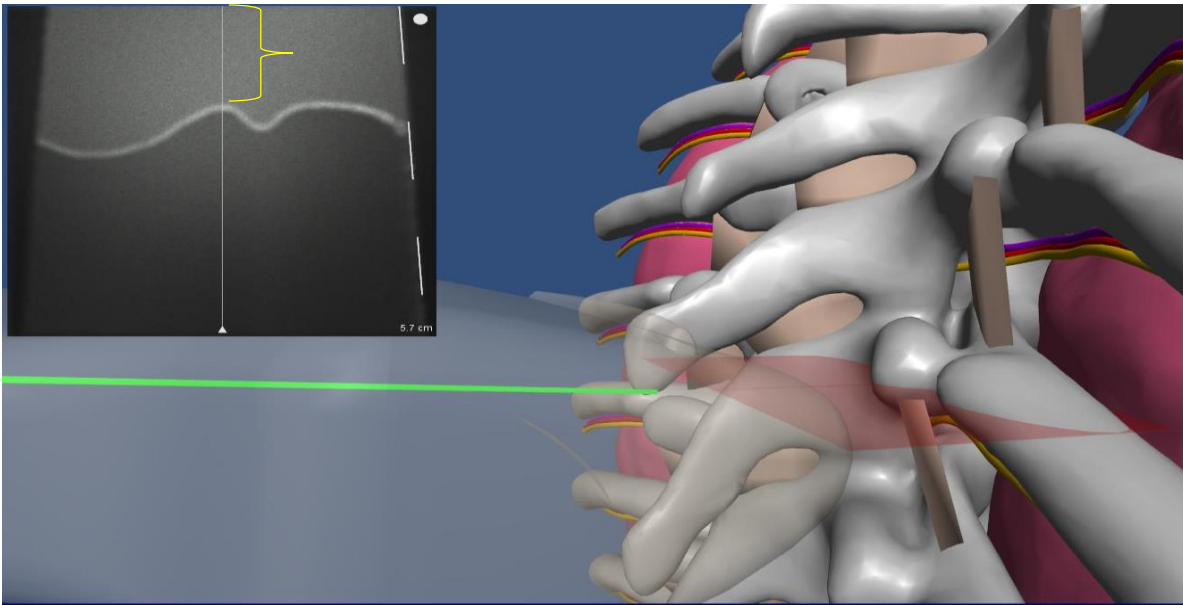


Delta TP-lung on the mixed virtual reality simulator



The US insonating plane is shown on the virtual images in color and correlate to the (virtual US) images in black and white in the left upper corners. Note the depth difference between TP (image on left) and pleura (image on right). In this case, the delta (yellow bracket) is close to 2 cm, so we can use 1 cm for IA and 5 mm for SA if needed without risk of lung injury.

Avoid excessive tissue compression with US transducer when measuring the depths from skin.



The depth from skin to TP on the left image is about 5 mm less than on the right due to excessive tissue compression from excess force exerted on the US probe. For the best accuracy, apply as little pressure to the US transducer as possible when measuring any depth.

Review questions

- Why do we use both axial and sagittal scans to mark TP tip, which one is used first?
- What is the rule of equal sided triangle?
- What should be in the middle of the US screen during TP marking?
- What is important for accurate depth measurements?
- How do you place the transducer on the skin for measurements and how do you adjust its angulation?
- How do you calculate SLD? Delta?
- Why is there a difference between US depth and needle depth (at least one reason)?